



International Journal of Fisheries and Aquatic Studies

ISSN: 2347-5129

(ICV-Poland) Impact Value: 5.62

(GIF) Impact Factor: 0.352

IJFAS 2015; 2(5): 366-369

© 2015 IJFAS

www.fisheriesjournal.com

Received: 21-04-2015

Accepted: 25-05-2015

Babatunde Akeem Saka

Department of Veterinary Public
Health and Preventive Medicine,
University of Ibadan, Ibadan,
Nigeria.

Olanike Kudirat Adeyemo

Department of Veterinary Public
Health and Preventive Medicine,
University of Ibadan, Ibadan,
Nigeria.

Ben Obukowho Emikpe

Department of Veterinary
Pathology, University of Ibadan.

Testes Development in Nigerian *Clarias gariepinus*, Burchell 1822

Babatunde Akeem Saka, Olanike Kudirat Adeyemo, Ben Obukowho Emikpe

Abstract

In this study, the morphometrical pattern of the testis and the histomorphology of the spermatogenesis of Nigerian *C. gariepinus* were studied using gross and histological techniques, with a view to providing support to further toxicological studies of this species. In this study, the developmental stages and therefore classification of the Nigerian and Turkish of *Clarias gariepinus* species were similar in the male. However the onset of puberty of the Nigerian specie of *Clarias gariepinus* was found to be considerably different from that of the Turkish species. Onset of puberty was at 5 months in the male with full maturation at 6 months while onset of puberty in the Turkish specie was at 9-10 months and full maturation at 12 months. It also revealed that while the Turkish species records 140g for the male, the Nigerian species recorded 900g for the male at full maturity.

Keywords: *Clarias gariepinus*, male, Nigerian, testis, spermatogenesis,

1. Introduction

Catfishes constitute a large group of freshwater fishes which are widely distributed throughout the world. They are especially diverse in larger rivers such as the Amazon and Zaire, in each of which several hundred species are found. Some catfish are armoured with heavy scales but most are scale-less. They vary in size from tiny parasitic species with a total length of less than 5 mm to giant forms such as some of the *Pangasius spp*, the Wels (*Silurus glanis*), the Vundu (*Heterobranchus longifilis*) and the African sharp-tooth catfish (*Clarias gariepinus*, Burchell 1822) which exceeds 30 kg in mass^[1].

Histology is an important tool to assess reproductive fish health and to show the initial signs of lesions or alterations not easily identifiable during the macroscopic examination of fish tissue. Results from a histological assessment can provide better insight into the environmental^[2].

However, it is important for the normal state of any animal to be well known in order to provide a template for comparison with suspected abnormal state. Yonkos *et al.*^[3] stated that identification of tissue lesions requires a baseline appreciation of normal tissue conditions, as histological alterations can occur in target organs that are not necessarily the result of toxicant exposure. An accurate histological assessment therefore requires knowledge and understanding of the normal histological structure of the organ and species in question.

Therefore baseline reproductive biology of fish is increasingly being studied to identify genetic or anthropogenic gonadal abnormalities as well as support the interpretation of experimental studies with potential endocrine disrupting chemicals (EDCs)^[4]. These chemicals can have adverse effects on the reproduction and development of fish populations. Findings have been published regarding EDCs and their subsequent effects on the gonadal histo-morphology of fish and *Lepomis macrochirus*^[5] and, *Rutilus rutilus*^[6]. Intersex has also been identified in *C. gariepinus* exposed to estrogen polluted water in South Africa^[7]. Apart from exposure to EDCs, certain metals have also been shown to target the testes of fish such as *Salvelinus fontinalis*^[8,9], *Carassius auratus*^[10], *Clarias batrachus*^[11,12] and *Oreochromis mossambicus*^[13]. Reference information on normal testis histology is therefore imperative to a better understanding of the effects of exposures to any anthropogenic chemical with the potential to disrupt testes histology and normal functions as well as abnormal genetic modifications.

At present, limited histological descriptions of testis histology exists for Nigerian *C. gariepinus* which could be used in gonadal histological assessment. Most histological studies

Correspondence

Babatunde Akeem Saka

Department of Veterinary Public
Health and Preventive Medicine,
University of Ibadan, Ibadan,
Nigeria.

use control groups to serve as a reference for normal histology. The limitation of the use of control group as reference is that in some gonadal histo-toxicity studies, control groups exhibit a range of histological characteristics not confirmed to be normal. Hence a comprehensive study on the gonadal development is necessary especially in Nigerian fishes since the period of maturity varies in fish and with culture conditions.

Cek and Yilmak ^[14] discovered that the Turkish *C. gariepinus* attained sexual maturity a year after hatching under standard laboratory conditions with initial detection of spermatozoa at 9 months of age and at 140 grams for the male. Cavaco *et al.* ^[15] also got similar results for maturity at 108 gram and 113 grams for male and female, respectively in the wild (ASI River) ^[16], while Schulz *et al.* ^[17] on the other hand observed an early maturation in male *C. gariepinus* with an initial spermatozoa detection at 6 months of age. Personal communications have reported successful utilization of Nigerian *C. gariepinus* of 5 months for spawning. The knowledge of the relationship between age, size and gonadal development is paramount for reproduction as well as to diagnose toxicity, abnormalities and their effects on the different stages of gonadal development. Therefore this study is intended to aid aquaculture development by providing reference data on reproduction in an indigenous specie.

2. Materials and Methods

2.1 Experimental Fish and System

Female and male broodstock fish were selected from a local fish supplier. They were transported to the aquaria unit of the department of veterinary public health and preventive medicine, faculty of Veterinary Medicine University of Ibadan. Sharptooth catfish larvae were obtained through the artificial reproduction method described by Hogendoorn and Vismans ^[18] via the DRY Method.

The eggs hatched within 1 or 2 days at 26 ± 1 °C. As soon as the eggs began to hatch, dead eggs and other dirt were removed by carefully siphoning these out. After hatching, the larvae were left in the happa and a flow through system was established in the first week after hatching. The aquarium system was housed inside an experimental room with a natural photoperiod (12 h light and 12 h dark). During the experiment the larvae were first fed pre-formed Artemia. After 20 days they were fed powdered trout feed (Coppens). Juveniles were fed trout feed pellets (Coppens). The fishes were then transferred to earthen ponds at the age of 1 month. Juveniles were fed pelletized floating feed (Coppens), with the adoption of a static water system in which case 80-90% of the water in the tank was changed daily before the morning feed. Adults received the same feed but of bigger pellet size (4.5-6mm). From the age 1 month up to 5 months, 4-5 fish from each pond were sampled. In sampling, each fish was weighed and recorded, total and focal lengths taken and recorded as well. They were then sacrificed and their sexes were recorded. Finally the gonads were harvested, weighed and preserved in Bouin's fluid.

2.2 Histological Procedures

At the end of the experiment, all the sampled fishes were sacrificed. The gonads of the sacrificed fish were taken and then fixed in Bouin's fluid. Gonad development was determined histologically by light microscopy. The developmental stages of testes were determined for each fish. Spermatozoa classification was based on the histological

criteria adapted from ^[19]. All slides were subjected to histological assessment using compound light microscopy (Olympus CX22). The developmental stages of the gonads were determined by identifying histological features. Subsequently, the sexual maturity/stage of the sample groups was confirmed.

3. Results

At age few hours to 8 weeks of age, a gross dissection of the fish samples revealed the absence of gonads. At this age, gonads were inactive and undifferentiated, and it was not possible to distinguish males from females.

3.1 Morphology

Grossly, the stages of testes development observed in the Nigerian specie of *C. gariepinus* is in four stages which were:

Stage I: Testes at this stage were generally small, silvery or translucent filaments, thinner and longer than stage I ovaries. The edges were rounded and appeared like a tube. This was seen at the onset of gonadal development, at 12 weeks post hatch.

Stage II: Testes were characterized by whitish to pinkish, relatively large and turgescient testes of circular section (Fig I). However, semen was not present within the sperm duct and even when squeezed, there was no expression of milt.

Stage III: Testes were characterized by larger, fuller and well-developed testes. The entire gonad or only some areas had a whitish color (Fig II). A slight pressure of the testes surface makes milt flow out of the spermiduct, which is a definite indication of the stage III testes. This is manifested at about five months.

Stage IV: Testes were still almost as large as stage III testes, but they were flaccid and empty. This stage is indicative of a male just after spermiation (spent stage).

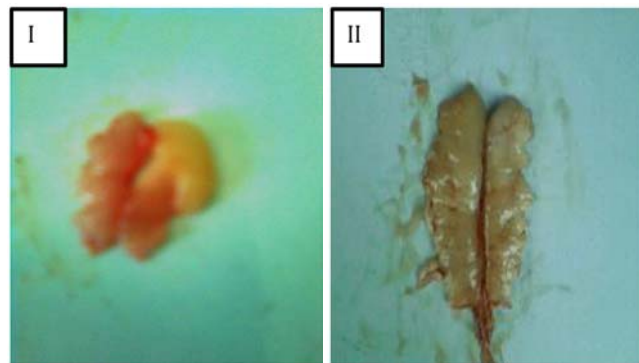


Fig I: Stage II testis.

Fig II: Stage III testis

3.2 Histo-morphology

3.2.1 Spermatogenesis

Four testicular stages were defined according to the maturation stage of the males. However, the terminology of spermatogenetic stages common to all vertebrates was used as it also allows for the correct description of spermatogenesis in fishes.

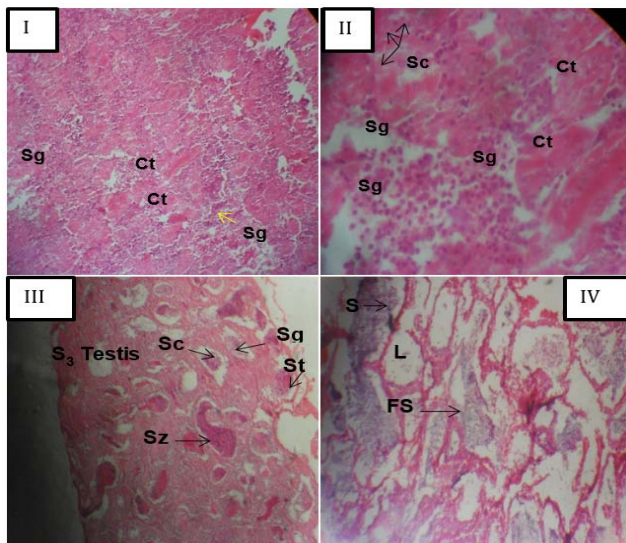
Stage 1 testes were characterized by the presence of spermatogonia nests embedded in abundant connective tissue.

Spermatogonia were visible but there were more somatic cells than spermatogonia, primary spermatocytes were also observed.

Stage 2: Had more spermatogonia, somatic cells and spermatocytes and less connective tissue.

Stage 3: All stages of spermatogenesis were visible. Spermatids and spermatozoa were darkly-stained. Spermatids were seen and were smaller than the spermatocytes, irregular in shape and more basophilic. Maturation was evidenced by the prevalence of spermatozoa which was seen to be strongly basophilic.

Stage 4 testes had a predominance of matured spermatozoa characterized by the emptying of spermatozoa into the lumen to create free spermatozoa.



Mag. X 400

Fig I: Stage 1 testes showing proliferation of spermatogonia and connective tissue

Fig II: Stage 2 testes showing an increased number of spermatogonia and spermatocytes (Sg: spermatogonia, Sc: spermatocytes and Ct: Connective tissues)

Fig III: Stage 3 testes, different stages of spermatogenesis may be identified by the absorption of the stains (Sc: Spermatocytes, Sg: Spermatogonia, St: Spermatids, Sz: Spermatozoa)

Fig IV: Stage 4 testes showing the emptying of the spermatozoa into the lumen (S: Spermatozoa, FS: Free Spermatozoa, L: Lumen).

4. Discussion

The study indicated that Nigerian *C. gariepinus* matured six months after hatching. Our study agrees with those by Yalcin *et al.* [16] and Schulz *et al.* [17] where they observed early maturation in male African *C. gariepinus* (spermatozoa first detected at 6 months of age). However it differs from that obtained for wild *C. gariepinus* whose age of first maturity was 1 year, when the body weights of the fishes were approximately 113 g for males [15].

Early maturation in fish has been achieved either by genetic selection or better nutrition, revealing a correlation between maturation and growth [20]. In their study, precocious maturation may have been achieved as a result of the feeding

conditions and genetic selection. Full maturation of *C. gariepinus* was found to be 6 months of age in this study. Schulz *et al.* [17] stated that sexual maturity is related to age in *C. gariepinus*; however, our observations showed that it was more determined by size rather than age. However, age cannot be totally excluded in the determination of puberty, especially since the age at puberty appears to decrease with increased size.

In this study on the Nigerian male sharp-tooth catfish, formation of spermatozoa was subdivided into 4 histological stages. Stage I testes contained spermatogonia only, while Stage II testes contained spermatogonia, primary and secondary spermatocytes, and meiotic germ cells. Stage III testes contained all germ cell stages, including spermatozoa which were still retained in the lamellae, while stage IV testes had the escape of the spermatozoa into the lumen. These findings are similar to those previously reported [19, 16, 21]. In the present study, testes were of the unrestricted type (anastomosing tubular type) in which spermatogonia were distributed throughout the testes, and the primary and secondary spermatocytes were motionless during puberty. These findings were also similar to those published [16, 21, 17]. During the study, milt could not be expressed when pressure was applied to fish's abdomen; they had to be sacrificed in order to obtain milt from the anterior part of the testes. These findings are also supported by similar studies [22, 23].

In conclusion, this study has shown that the Nigerian specie of African sharptooth catfish *C. gariepinus* matured 5 months after hatching which is earlier than the Turkish specie thus indicating a specie variation. It is as well worthy of note that the Nigerian specie of *C. gariepinus* grows faster and the adult size are bigger than the Turkish specie. At their puberty (5 months) the average weight for the male was 700g. These results suggest that a 6 months old Nigerian *C. gariepinus* can be used as brood stock for seed production in captivity.

5. References

1. Bruton MN. The breeding biology and early development of *Clarias gariepinus* (pisces, clariidae) in Lake Sibaya, South Africa, with a review of breeding species of the subgenus *Clarias* (*Clarias*), Trans. Zool. Soc. London, 35:1-45. Buchanan. Z Mikrosk Anat Forsch 1966; 75:63-73.
2. Short S, Meyers TR. Histology for finfish. NWFHS laboratory procedures manual. Version 1.0. Alaska Fish and Game C.F. Division, Anchorage, AK, 2001.
3. Yonkos LT, Kane AS, Reimschuessel R. Fathead minnow histology atlas: Worldwide web outreach and utilization. Mar. Environ. Res 2000; 50:312
4. Jensen KM, Korte JJ, Kahl MD, Pasha MS, Ankley GT. Aspects of basic reproductive biology and endocrinology in the fathead minnow (*Pimephales promelas*). Comp. Biochem. Phys. Comp. Biochem. Physiol. C 2001; 128:127-141.
5. Maxwell LB, Dutta HM. Diazinon-induced endocrine disruption in bluegill sunfish, *Lepomis macrochirus*. Ecotoxicol. Environ. Saf 2004; 60:21-27.
6. Bjerregaard LB, Korsgaard B, Bjerregaard P. Intersex in wild roach (*Rutilus rutilus*) from Danish sewage effluent-receiving streams. Ecotoxicol. Environ. Saf 2005; 64:321-328.
7. Barnhoorn IEJ, Bormman MS, Pieterse GM, Van Vuren JHJ. Histological evidence of intersex in feral sharptooth catfish (*Clarias gariepinus*) from an estrogen-polluted

- water source in Gauteng, South Africa. *Environ. Toxicol.* 2004; 19:603-608.
8. Sangalang GB, O Halloran MJ. Cadmium-induced testicular injury and change of androgen synthesis in brook trout. *Nature* 1972; 240:470-471.
 9. Sangalang GB, Freeman HC. Effects of sublethal cadmium on maturation and testosterone 11-ketotestosterone production in vivo in brook trout. *Biol. Reprod* 1974; 11:429-435.
 10. Tafanelli R, Summerfelt RC. Cadmium-induced histopathological changes in goldfish. In: *The pathology of fishes*. W. E. Ribelin, G. Migaki (Eds), University of Wisconsin Press, Madison, WI, 1975, 613-645.
 11. Katti SR, Sathyanesan AG. Chronic effects of lead and cadmium on the testis of the catfish *Clarias batrachus*. *Environ. Ecol. Stat* 1985; 3:596-597.
 12. Kirubakaran R, Joy KP. Toxic, Beams effects of mercury on testicular activity in the freshwater teleost, *Clarias batrachus* (L.). *J. Fish Biol* 1992; 41:305-315.
 13. Pieterse GM. Histopathological changes in the testis of *Oreochromis mossambicus* (Cichlidae) as a biomarker of heavy metal pollution. Doctoral thesis, Faculty of Science, Rand Afrikaans University, Johannesburg. Press, New York, USA, 1983, 223-275.
 14. Cek S, Yilmaz E. Gonad development and sex ratio of Sharp-tooth catfish (*Clarias gariepinus* Burchell, 1822) cultured under laboratory conditions. *Turk. J. Zool.* 2007; 31:35-46.
 15. Cavaco JEB, Vischer HF, Lambert JGD, Goos HJTh, Schulz RW. Mismatch between patterns of circulating and testicular androgens in African catfish, *Clarias gariepinus*. *Fish Physiol. Biochem* 1997; 17:155-162.
 16. Yalçın S, Solak K, Akyurt I. Certain reproductive characteristics of the African Catfish (*Clarias gariepinus* Burchell, 1822) living in the River Asi, Turkey. *Turk. J. Zool* 2001; 25:453-460.
 17. Schulz RW, Van der Corput L, Janssen-Dommerholt J, Goos HJTh. Sexual steroids during puberty in male African catfish (*Clarias gariepinus*): serum levels and gonadotropin- stimulated testicular secretion in vitro. *J. Com. Physiol B* 1994; 164:195-205.
 18. Hogendoorn H, Vismans MM. Controlled propagation of the African catfish; *Clarias lazera* (C & V) artificial reproduction. *Aquaculture* 1980; 21:39-53.
 19. Grier HJ. Cellular organization of the testis and spermatogenesis in fishes. *Am. Zool.*, Cambridge University Press 1981; 21:345-357
 20. Le Bail PY. Growth-reproduction interaction in salmonids. In: *Reproduction in Fish, Basic and Applied Aspects in Endocrinology and Genetics* (Eds. Y. Zohar and B.Breton). Les Colloques de IÖINRA, Paris, 1996, 91-107.
 21. Cavaco JEB. Sex steroids and spermatogenesis in the African catfish (*Clarias gariepinus*). *Archives of Androlog* 2005; 51:99-107.
 22. Wu C, Patino R, Davis KB, Chang X. Localization of estrogens receptor α and β RNA in germinal and non-germinal epithelia of the Channel catfish testis. *Gen. Comp. Endoc* 2001; 124:12-20.
 23. Vieira's ATM, Fessehaye Y, ter Veld M, Schulz RW, Komen J. Hand-stripping of semen and semen quality after maturational hormone treatments, in African catfish *Clarias gariepinus*. *Aquaculture* 2002; 213:373-386.