E-ISSN: 2347-5129
P-ISSN: 2394-0506
(ICV-Poland) Impact Value: 5.62
(GIF) Impact Factor: 0.549
IJFAS 2020; 8(5): 220-225

www.fisheriesjournal.com
Received: 12-07-2020
Accepted: 21-08-2020

Sabina Sultana
Professor, Department of Zoology, University of Rajshahi, Rajshahi-6205, Bangladesh

Fahmida Akhter
Department of Zoology, University of Rajshahi, Rajshahi-6205, Bangladesh

Sahadat Hossain
Department of Zoology, University of Rajshahi, Rajshahi-6205, Bangladesh

Corresponding Author:
Sabina Sultana
Professor, Department of Zoology, University of Rajshahi, Rajshahi-6205, Bangladesh

Cytogenotoxic effects of acid dye on *Channa punctatus* (Bloch)

Sabina Sultana, Fahmida Akhter and Sahadat Hossain

Abstract
The aim of this present investigation was to assess morphological and behavioural changes and to evaluate the histological changes of liver, stomach and intestine of *Channa punctatus* (BLOCH) at different concentration of acid dye. The study was conducted during the period November, 2016 to August, 2017 at Fisheries Research Laboratory, Department of Zoology, University of Rajshahi, Bangladesh. 40%, 60% and 80% mortality were recorded at 0.07, 0.09 and 0.2ml/L concentration of acid dye. Histopathological changes were observed in liver, stomach and intestine of the treated fish compared to control fish. The experimental fish showed- dilation of sinusoid, enlarged central vein, vacuolization of hepatocyte, hemorrhage and necrosis in liver; degeneration in the layer, acute depletion of epithelium, necrosis and hemorrhage in stomach; complete destruction of villi, mass depletion of epithelium, and the rapture in the layer in intestine. The study revealed toxic effects of acid dye on *C. punctatus*.

Keywords: Cytogenotoxic, acid dye, morphological, behavioural, *Channa punctatus*

1. Introduction
Study related to environmental pollution have fascinated the attention of researchers all over the year. Advancement of modern technology and the use of synthetic and artificial chemicals to rectify different industrial products led to a major problem with respect to the release of wastes into the aquatic ecosystems. Wastewater run-offs from different dye-stuff industries and textiles carry substantial quantity of synthetic dyes as well as detrimental chemicals [1, 2]. Almost over ten thousand synthetic dyes are now commercially available in the global market. During the dyeing process, nearly 10-15% of dyes are discharged out in the form of effluents. Dyes persevere in water bodies for relatively a long time and simultaneously the aquatic creatures also in contact with them for a long time together. Most of the dyes are non-decomposable, mutagenic, carcinogenic and hypothetically toxic to human and other living organisms, specially to aquatic animals [3-5]. Acid dye is very common in Bangladesh that is used in most of the textile dyeing and washing industries. But acid dye is already found to be harmful to brain, liver, kidney and the reproductive system of fish population [6].
Channa punctatus (BLOCH) (Order: Channiformes; Family: Channidae), commonly known as "Snake-headed fish" in English and "Taki (Fish)" in Bengali [7], can be found in almost aquatic habitats like rivers, lowland, lakes, canals, rice fields, ponds etc. Snake-headed fishes were abundantly found in almost every freshwater bodies of Bangladesh only a few years ago. Every year the production of snakehead fish is decreasing and the aquatic environment pollution is one of the major causes behind it [8].
In this study, *C. punctatus* were treated with acid dye with three different concentration and the changes were observed for a certain time. The objective of this present study was to observe morphological and behavioural changes and to evaluate the histopathological changes of liver, stomach and intestine of *C. punctatus* at different concentration of acid dye.

2. Materials and methods
2.1 Study area and study period
The study was conducted at the Fisheries Research Laboratory of the Department of Zoology, University of Rajshahi, located at Sir Jagadish Chandra Bose building of the University. The research was performed during the period from November, 2016 to August, 2017.

2.2 Collection & pre-exposure acclimation of experimental fish
Healthy and active specimens of freshwater fish, *C. punctatus* were collected as experimental fish from the fisherman of the fish landing center of Rajshahi. The live specimens were transported to the laboratory. Fishes were acclimatized for two weeks in laboratory conditions. The fishes were fed with two times (8am, 4pm) in a day. The water medium used was changed twice a day. This helped to remove the unused feed, fecal matter and other unwanted particles.

2.3 Dye collection, dose estimation and exposure to acid dye
To conduct this study, the acid dye was collected from a retailer shop in Rajshahi town. Doses of acid dye were estimated and the doses of acid dye were 0.07, 0.09 and 0.2ml per liter water. Each dose was measured by micropipette and mixed with aquarium water. Four glass aquaria (with 50cm, 30cm, 20cm) were taken and washed with detergent and 0.1% of potassium permanganate to make the aquaria germ free. After acclimatization the experimental fishes were transported to glass aquaria in laboratory. For histopathological studies, the fishes were exposed to 0.07, 0.09 and 0.2ml acid dye per liter water in four glass aquaria separately. The experimental fishes were kept under the observation around for 21 days. The experimental conditions and mortality were observed. At the end of exposure, the survival and dead fishes used for histological study. A control aquarium was also maintained under the laboratory condition.

2.4 Calculation of RPS (Relative percentage of survival)
Relative percentage of survival (RPS) was calculated according the following formula [9]:
RPS= (1- % mortality in treatment with dye / % mortality in control) × 100.

2.5 Procedures of preparing histological slides
2.5.1 Dissection and tissue preservation
The fishes were sacrificed by decapitation and dissected after the completion of exposures to the different concentrations of acid dye. The target organs were surgically removed and thoroughly washed in cold normal saline solution (0.85% NaCl). The tissue of target organs like intestine, stomach and liver were fixed in Bouin's fluid and then they were processed by standard procedure to routine microtome technique.

2.5.2 Tissue processing and slide preparation
The most commonly used method of studying tissues is done by preparing histological slides. The slide should be processed in a proper way so that it confidently reflects the real nature of the tissues of any specimen. The preserved tissues should go through a series of phases before observation. The total phases of preparing permanent histological slide is given following [10-13]:

a) Fixation
b) Washing and Dehydration
c) Dealcoholizing
d) Infiltration
e) Embedding with paraffin
f) Trimming and block setting
g) Cutting paraffin ribbon
h) Stretching of small pieces of ribbon on the slides
i) Staining

2.6 Microscopic examination
The microscopic views of the tissues were taken at a resolution power with the help of light microscope. All the slides were observed under low and high resolutions for their histological findings. Microscopic examination showed the histological abnormalities and differences from the control to the treated groups of different target organs of *C. punctatus*.

3. Results
3.1 Morphological and behavioural observation
Morphological and behavioural changes in the fishes were observed after they were introduced into the dye dissolved water. They tried to jump out of the water soon after they were introduced into the medium. During the initial hours, their movement was very fast with erotic jumping and they were hyperactive. Air gulping behaviour was increased rapidly and tends to decrease after a short period. Grouping behaviour was found to be distorted. Two major behavioural changes such as hypo activity and lethargy were noticed in fish that were exposed to higher concentrations of dyes after a short period of time. In higher concentrations, after some days the fishes lost their equilibrium, remained motionless, excess mucus were spread all over the body surface and ultimately death occurred with slightly bulged out eyes.

Table 1: External view of *C. punctatus* at different concentration of acid dye

Parameter of external view	Control fish	Concentration of treated acid dye (ml/L)		
		0.07	0.09	0.2
Fin	No change	Less narrow	Narrow	Reduced
Scale	No change	Unsmooth	Unruly	Rough
Eye	No change	Colour fade	Blow up	More enlarge
Gill	No change	Fade	Brown	Brownish
Operculum	No change	Smoothless	Unruly	Rough
Mucose	No change	Increased	Increased	Exceedingly
Body colour	Turn pale	Radish	Radish	Radish

Table 2: Weight loss of *C. punctatus* at different concentration of acid dye

Weight (gm)	Control fish					Concentration of acid dye (ml/L)														
						0.07					0.09					0.2				
Sample	1	2	3	4	5	1	2	3	4	5	1	2	3	4	5	1	2	3	4	5
Initial Weight	35	34	36	34	35	36	34	35	35	34	34	36	34	35	35	36	33	35	35	34
Death weight	32	31	33	33	32	32	32	33	30	30	29	33	28	31	30	29	26	29	28	27
Net weight	3	3	3	1	3	4	2	2	5	4	5	3	6	4	5	7	7	6	7	7

3.2 Mortality observation

The effects of different concentrations and exposure period of acid dye as represented by the cumulative percentage of mortality of *C. punctatus* is shown in the table 3. The experimental fishes were exposed to toxic environment of 0.07, 0.09, 0.2 ml/L concentrations of acid dye. No mortality was observed in control fish in 21 days, whereas 2 and 3 fishes were died within 21 days pertaining 40% and 60% cumulative mortality in 0.07ml/L and 0.09ml/L doses of dye respectively.

Table 3: LD_{50}, 95% confidence limits, χ^2 with regression equation and other statistical values of acid dye application against *C. punctatus*

LD_{50}		0.0807624ml/L
Regression equation		Y = 3.060244 + 2.138157 X
95% confidence limit	Upper	0.1832339
	Lower	0.0355970
$\chi 2$ value		0.1021239
Coefficient of correlation		r = 0.942155
F-distribution value		6.915073
F-distribution table value		5.987378
Variance		0.006867

From these above statistical data, it is observed that there is high correlation between doses of acid dye and mortality rate of *C. punctatus*.

3.3 Histopathological effects

During experimental period noticeable histopathological changes in the liver, stomach and intestine also behaviour of treated fishes were observed. For comparison with the treated specimens from untreated control fish, both specimens were examined under the light microscope to observe the histopathological alterations. The microscopic observations were reported for each organ and the intensity of changes is presented by the figures 1, 2 and 3.

3.3.1 Effect of acid dye on liver of *C. punctatus*

The present study demonstrated that the hepatocytes found normal, homogenous cytoplasm and a large central or sub central spherical nucleus is found in the control fish. Discrete pathological changes were noticed in the liver of the fishes exposed to acid dye at different concentrations. The most common changes showed in treated fishes are- hepatocytes vacuolization, fatty degeneration of the liver, changes in metabolic activity, changes in liver parenchyma necrosis. In specimen treated with 0.07ml/L acid dye, enlarged central vein and dilation of sinusoid is observed. Hemorrhage and dilation of sinusoid is found in fish's liver treated with 0.09ml/L acid dye. Maximum destructive effect was found in fish treated with acid dye in a concentration of 0.2ml/L. The overall changes were- i) the liver cell was affected; ii) showed necrosis; and iii) vacuolization was found in hepatocyte.

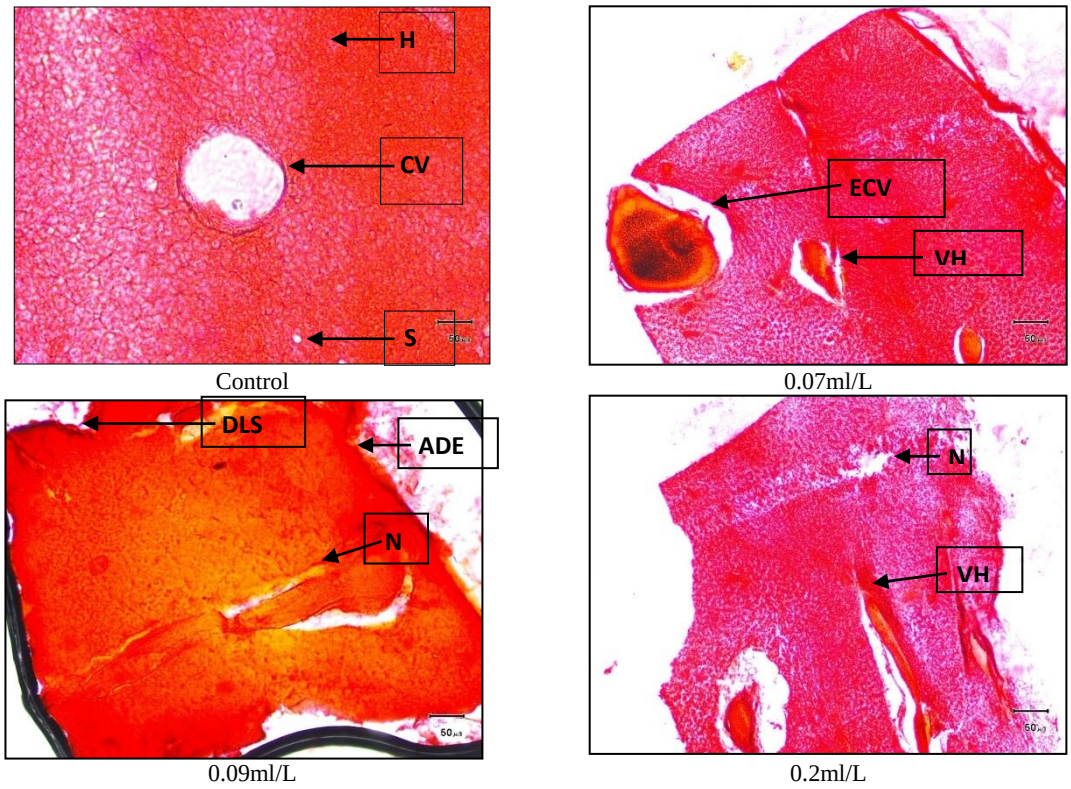

Fig 1: Micrographs of liver of control and exposed *C. punctatus* with acid dye at different concentrations (T.S. 4x) [H=Hepatocyte; CV= Central Vein; S= Sinusoid; ECV=Enlarged Central Vein; VH=Vacuolization of hepatocyte; DLS=Degeneration in Layer of Stomach; ADE=Acute Depletion of Epithelium; N=Necrosis]

3.3.2 Effect of acid dye on stomach of *C. punctatus*

The slide observation revealed that stomach shows normal columnar epithelium, muscularis, and sub-mucosa with blood capillary and serosa with longitudinal and circular muscle in control fish. In specimen treated with 0.07ml/L dye, no histological changes were found also. In specimen treated with 0.09ml/L concentration of acid dye, the major changes were- i) degeneration in the stomach layer; ii) acute depletion of epithelium; iii) necrosis also found in stomach cell. The most devastating changes were observed in fishes stomach treated with 0.2ml/L concentration of acid dye. The major findings were- i) necrosis occurred in different portion; ii) hemorrhage found; iii) acute depletion of columnar epithelium; and iv) breakdown in stomach layer.

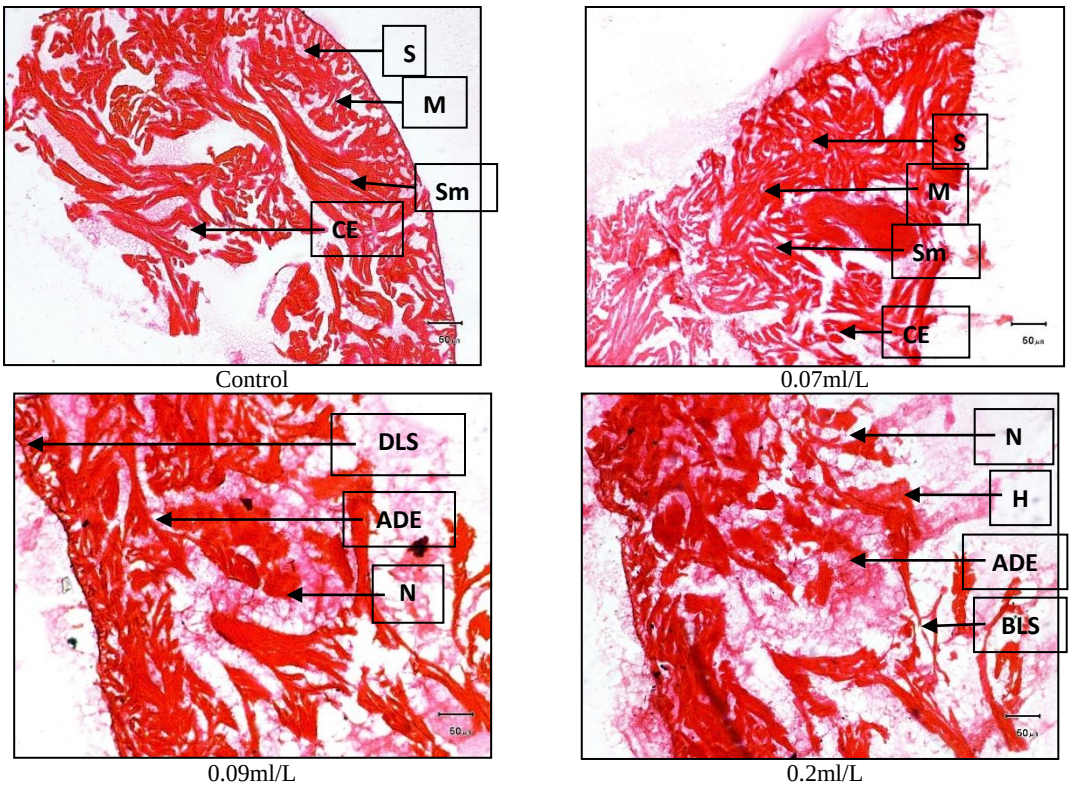

Fig 2: Micrographs of stomach of control and exposed *C. punctatus* with acid dye at different concentrations (T.S. 4x) [S=Serosa; M=Muscularis; Sm=Submucosa; CE=Columnar epithelium; DLS= Degeneration in the layer of stomach, ADE= Acute depletion of epithelium, N= Necrosis; H= Hemorrhage; BLS= Breakdown in the layer of stomach]

3.3.3 Effect of acid dye on intestine of *C. punctatus*

In control fish, intestine showed the normal structure containing normal condition of mucosa, sub-mucosa, muscularis, serosa and villi during microscopic observation. No histopathological damage occurred in treatment with 0.07ml/L concentration. When the fish was treated with 0.09ml/L concentration of acid dye, the intestine showed partial degeneration of villi and depletion of epithelium. Major histopathological changes were observed in treatment with 0.2ml/L concentration of acid dye. The intestine showed comparatively serious changes than other concentration. The changes were- i) mass depletion of epithelium; ii) degeneration of cell layer; iii) complete destruction of villi; and iv) Rapture in layer of intestine.

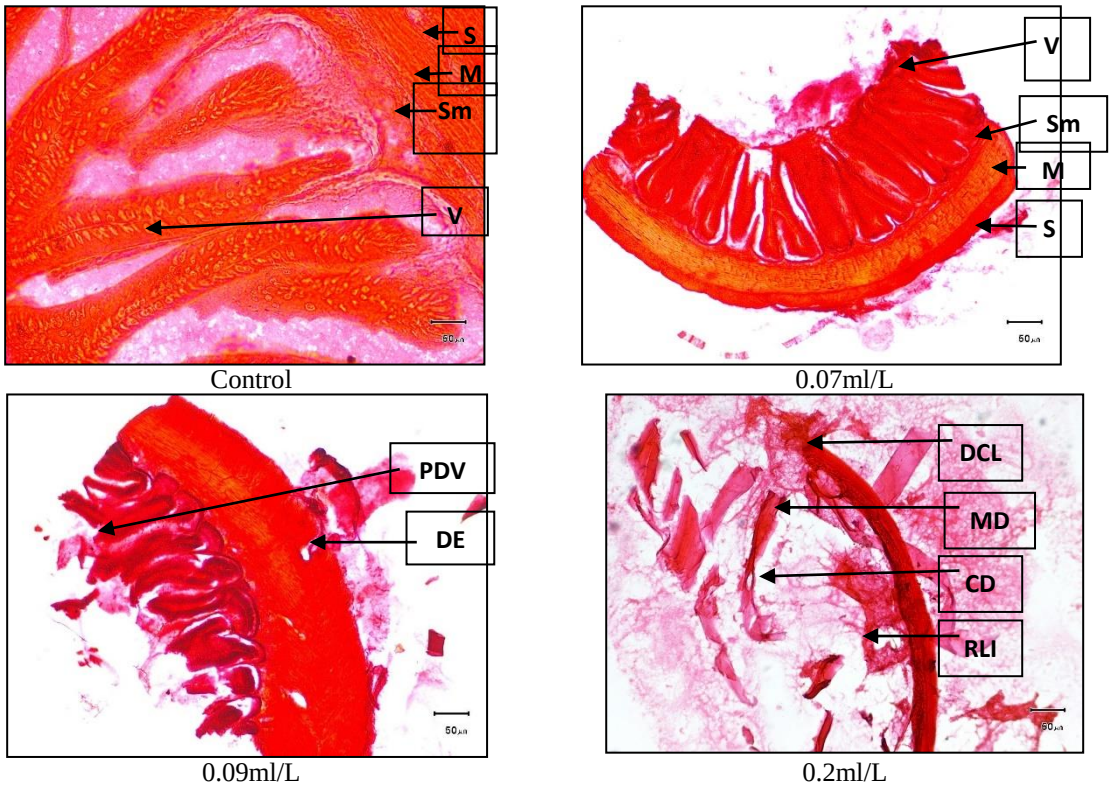

Fig 3: Micrographs of stomach of control and exposed *C. punctatus* with acid dye at different concentrations (T.S. 4x) [S= Serosa; M= Muscularis; Sm= Sub mucosa; V= Villi; PDV = Partial degeneration of villi; DE= Depletion of epithelium]

4. Discussion

Bangladesh is one of the most densely populated country. Rapid growth of population demands more protein for ensuring their daily average protein intake. It has been shown in a previous study that fish supplements about 60% of Bangladeshi people's daily animal protein intake [14]. But an investigation on Bangladesh's inland fish and fisheries sectors revealed that 54 varieties of fishes have already become extinct and some are in endangered condition [8]. Presence of dyes in surface and subsurface layer of aquatic system brings serious threat to the overall epidemic and socio-economic pattern inside, people who live in these areas are utilizing surface water for their house hold washing, bathing, irrigation, fish culture and other necessary work [15]. Another study found acid dyes pose mutagenicity, genotoxicity, carcinogenicity and lethal effects to humans as well as other animals [16]. So, the disposal of acid dyes into the environment specifically from the textile and garment industries is one of the major threats to human as well as other aquatic organisms.

The outcomes of the present study receive supports from the previous studies conducted on testing the effect of several dyes to different fish species conducted by previous researchers [17-19]. This study is in agreement with the earlier one of Kirandeep *et al*. [20], who showed that cytogenotoxicity of Acid Blue-113, azo dye was concentration dependent and caused damage to all studied target tissues (the brain, liver, kidneys and the reproductive system) of *C. punctatus*. The toxic effect of acid dye reveled from this study is similar to experiment conducted by Al-Sabti, evidenced the genotoxic effect of chlorotriazine Reactive Azo Red 120 textile dye in aquatic ecosystems [21]. Behavioural changes such as fast jerking, frequently jumping, erratic swimming, spiraling, convulsion and tendency to escape from the aquarium, found in this current investigation also agree with that of Selvaraj, who detected the abnormal behaviour changes like erratic swimming, hyper excitation, rapid opercular movement and thick mucous covering; while histopathological changes such as enlargement of primary gill bar and detached secondary gill bar observed in gill and also infiltration of haematocytes into lumen was also seen in teleost fish *Poecilia recticulata* [22].

Morphological changes in gills found in this study matched with some previous parallel observations. Hyperplasia, aneurism, lifting of gill epithelium, curved secondary gill lamellae degenerated central axis, were observed in the gills of dye exposed fingerlings [23, 24]; in contrast to Srivastava *et al.* showed that, in presence of dye or other toxicants, epithelial lifting has occurred as a protective response to keep the distance between secondary gill lamellae and toxicant, which makes secondary gill lamellae curvier and finally, it might affect the total gill's structure and functions [25]. Histopathological changes in liver and intestine, found in this study showed a great affiliation with the previous investigations which confirmed that after the exposure of textile dyeing effluent, fish liver shows cytoplasmic vacuolation and bunching of nuclei and intestine results in the breakdown of intestinal villi and infiltration of haemocytes into the lumen [26].

5. Conclusion

The findings of this present study conclude that different concentrations of acid dye produced different level of morphological, behavioural and histopathological changes in *C. punctatus*. Looking to the cytogenotoxic and histotoxic potential of acid dye, we should decrease the expose of acid dye in the environment through implementing essential accurate pre-treatment of wastewater from textile and dying industries before release. This study also recommends proper inspection of acid dye toxicity before using it in any industry. To save the fish population from threats, we should realize the injurious effects of acid dye and establish reliable waste water treatment in textile and dyeing industries.

6. Acknowledgement

The authors willingly acknowledge the chairman of Department of Zoology, University of Rajshahi, Bangladesh for giving the access to use all the laboratory facilities from Fisheries Research Laboratory to carry out this current study.

7. References

1. Puvaneswari N, Muthukrishnan J, Gunasekaran P. Toxicity assessment and microbial degradation of azo dyes. Indian Journal of Experimental Biology. 2006; 44:618-626.
2. Khalid A, Arshad M, David E, Crowley DE. Accelerated decolorization of structurally different azo dyes by newly isolated bacterial strains. Applied Microbiology and Biotechnology. 2008; 78(1):361-369.
3. Ogugbue CJ, Oranusi NA. Toxicity of azo dyes to the freshwater shrimp (*Desmocaris trispinosa*). International Journal of Natural and Applied Sciences. 2006; 1:37-44.
4. Padhi BS. Pollution due to synthetic dyes toxicity & carcinogenicity studies and remediation. International Journal of Environmental Science. 2012; 3:940-955.
5. Rinde E, Troll W. Metabolic reduction of benzidine azo dyes to benzidine in the rhesus monkey. Journal of the National Cancer Institute. 1975; 55:181-182.
6. Adams DH, Onorato GV. Mercury concentrations in red drum, *Sciaenops ocellatus*, from estuarine and offshore waters of Florida. Marine Pollution Bulletin. 2005; 50(3):291-300.
7. Nahar L, Hoque MM, Fatema MK, Ahmed ZF. Age and Growth of Spotted Snakehead *Channa Punctata* (Bloch, 1793) of Kajla Beel in North East Bangladesh. International Journal of Agriculture Innovations and Research. 2017; 6(2):289-292.
8. Rahman MM, Hossain MA, Miah MAM, Rahman MM. An investigation into fisheries knowledge of fish farmers towards fish culture management. Bangladesh Journal of Training and Development. 1989; 1(1):9-16.
9. Amend DF. Potency testing of fish vaccines. Developments in Biological Standardization. 1981; 49:447-454.
10. Clayden EC. Practical section cutting and staining. Edinburgh: Churchill Livingstone, 1971.
11. Hopwood D. Fixation and fixatives. In Bancroft J and Stevens, A eds. Theory and practice of histological techniques. New York: Churchill Livingstone, 1996.
12. Carson FL. Histotechnology. 2nd ed. Chicago: ASCP Press, 2007.
13. Winsor L. Tissue processing. In Woods A and Ellis R eds. Laboratory histopathology. New York: Churchill Livingstone, 1994; 4.2-1-4.2-39.
14. DoF. National fish week, compendium (In Bengali), Department of Fisheries. Ministry of Fisheries and Livestock, Government of Bangladesh, Dhaka, 2016.
15. Filippone Trowbridge Peggy. Food Color Additives. Retrieved September 8, 2016.

16. Correia VM, Stephenson TS, Judd SJ. Characterization of textile wastewaters: A review. Environmental Technology. 1994; 15:917-929.
17. Avni P, Barot J. Determination of genotoxic effect of azo dye CI RR 120 on fish *Catla catla*. Biotechnological Research. 2016; 2:77-80.
18. Cavas T, Ergene-Gozukara S. Micronuclei, nuclear lesions and interphase silver-stained nucleolar organizer regions (AgNORs) as cyto-genotoxicity indicators in *Oreochromis niloticus* exposed to textile mill effluent. Mutation Research. 2003; 538:81-91.
19. Parmar A, Shah A. Cytogenotoxicity of azo dye Reactive Red 120 (RR120) on fish *Catla catla*. Environmental and Experimental Biology. 2019; 17:151-155.
20. Kirandeep K, Arvinder K, Rajvir K. Cytogenotoxicity of azo dye acid blue-113 (AB-113) to *Channa punctatus* (BLOCH). Journal of Environmental Research and Development. 2015; 9(3):547-554.
21. Al-Sabti K. Chlorotriazine reactive azo red 120 textile dye induces micronuclei in fish. Ecotoxicology and Environmental Safety. 2000; 47:149-155.
22. Selvaraj D, Leena R, Kamal DC. Toxicological and histopathological impacts of textile dyeing industry effluent on a selected teleost fish *Poecilia reticulata*. Asian Journal of Pharmacology and Toxicology. 2015; 03(10):26-30.
23. Wood MC. Toxic response of the gills. in New prospective: Toxicology and environment: target organ toxicity in marine and freshwater teleosts. D. Schlenk and W. H. Benson, Eds. London: Taylor and Francis, 2001, 1.
24. Jagruti B. Evaluation of Azo dye toxicity using some haematological and histopathological alterations in fish *Catla catla*. International Journal of Biological, Food, Veterinary and Agricultural Engineering. 2015; 9(5):388-391.
25. Srivastava AK, Sinha R, Singh ND, Srivastava SD. Histopathological changes in a freshwater catfish, *Heteropneustes* fossilis following exposure to malachite green. Proceedings of the National Academy of Sciences of India, Biological Sciences. 1998; 68(B):253-257.
26. Athira N, Jaya DS. The use of fish biomarkers for assessing textile effluent contamination of aquatic ecosystems: A review. Nature Environment and Pollution Technology. 2018; 17(1):25-34.