E-ISSN: 2347-5129
P-ISSN: 2394-0506
(ICV-Poland) Impact Value: 5.62
(GIF) Impact Factor: 0.549
IJFAS 2018; 6(5): 52-57

www.fisheriesjournal.com
Received: 25-07-2018
Accepted: 30-08-2018

Harton Arfah
Aquaculture Department, Faculty of Fisheries and Marine Science, Bogor Agricultural University. Jl. Agatis, IPB Dramaga, Bogor West Java, Indonesia

Agus Oman Sudrajat
Aquaculture Department, Faculty of Fisheries and Marine Science, Bogor Agricultural University. Jl. Agatis, IPB Dramaga, Bogor West Java, Indonesia

Muhammad Agus Supriyadi
Aquaculture Department, Faculty of Fisheries and Marine Science, Bogor Agricultural University. Jl. Agatis, IPB Dramaga, Bogor West Java, Indonesia

Muhammad Zairin
Junior, Aquaculture Department, Faculty of Fisheries and Marine Science, Bogor Agricultural University. Jl. Agatis, IPB Dramaga, Bogor West Java, Indonesia

Correspondence
Harton Arfah
Aquaculture Department, Faculty of Fisheries and Marine Science, Bogor Agricultural University. Jl. Agatis, IPB Dramaga, Bogor West Java, Indonesia

Gonad maturation of female striped catfish *Pangasionodon hypophthalmus* (Sauvage, 1878) using combination of pregnant mare serum Gonadotropin+Antidopamine, Vitamin E, and curcumin extract mixed feed outside its spawning season

Harton Arfah, Agus Oman Sudrajat, Muhammad Agus Supriyadi and Muhammad Zairin

Abstract
Reproductive engineering for gonadal maturation process is mostly related with four factors such as, environmental signals, environmental signals, reproductive organs, hormonal and nutrition. This research was conducted to obtained mature gonad of Striped Catfish, *Pangasianodon hypophthalmus* utilized three kinds of materials with eight treatments which is (PMSG hormone + Antidopamine), Vitamin E, and Turmeric. While, the experimental designed consisted of K (Control), HEKu (Hormon + Vitamin E + Turmeric), HE (Hormone + Vitamin E), HKu (Hormone + Turmeric), Eku (Vitamin E + Turmeric), H (PMSG + Antidopamine), E (Vitamin E), and Ku (Turmeric) with egg (5%) to the feed as a binder. This research was done by feeding fish with treated feed for twelve weeks. Fish growth showed no significant difference between treatments (P>0.05), but EKu treatment had the lowest growth. Fish hepatosomatic and gonadosomatic indices showed no difference before treated, but showed variation after 6 weeks of feeding.. Egg diameters were increased in line with the rearing duration. K and H treatment has the highest estradiol concentration in week-12. Testosterone and estradiol concentration had two peaks in all treatment except HKu which had three peaks at two, six, and ten weeks of rearing. Histological analysis showed that feeding with combination of hormone and turmeric (HKu) gave faster gonad development than other treatment. The result of this research concluded that (PMSG + Antidopamine) and turmeric in feed was able to accelerate the gonadal maturation in striped catfish.

Keywords: patin, gonadal maturation, (hormone, vitamin E, turmeric), feed

Introduction

Striped catfish, *Pangasionodon hypophthalmus* is widely cultured in Indonesia, especially in Java, Sumatera and Kalimantan. But its production in Indonesia was declined from 2014–2016, from 266.107 to 249.941 tons/year [6]. Striped catfish usually matured and spawns on rainy season in the wild [14]. But it is still hard to manipulate its gonadal maturation outside its spawning season in captivity. Mature fish, especially for female is scarce outside spawning season. It is hard to find mature broodstocks with eggs and make the fish to spawn. It is primarily due to the uncertain weather and extended dry season in the past 5 years [1]. Reproduction manipulation for this fish is needed in order to get mature broodstocks outside its spawning season.

Fish reproduction could be manipulated by modifying its environment signal, reproduction organ and hormone or chemical induction [20]. Hormonal induction becomes one of the most effective and easiest way to manipulate fish reproductions nowadays [11]. There are several kinds of hormones and chemicals that used to induce fish maturation and ovulation: fish Gonadotropin hormone (either follicle stimulating (FSH), luteinizing hormone (LH) or both), anti-dopamine (AD), human chorionic gonadotropin (HCG), and pregnant mare serum gonadotropin (PMSG) [5]. Aside to hormone, nutritional enrichment could also apply to help fish gonad maturation. Tocopherol (Vitamin E) supplementation on feed could trigger fish maturation [7, 16] and egg quality [19]. Vitamin E is also relatively easy to be obtained and its supplementation method is easy to be apply.

The aim of this study is to evaluate the role of combination of hormones, vitamin E and turmeric for the maturation of female catfish through the feed. We mixed PMSG with D to enhance the effects, and accelerate fish maturation. Since the fish will forced to mature outside its spawning season, we assumed that its reproduction organs including liver will have higher activity than usual.

Materials and Methods

Fish

The fish used in this study (n = 200) were all virgin female weighed 1.975 ± 0.083 kg (mean ± SD) obtained from local fish farm. Fish were reared for one week in pond and fed with commercial pellet feed (protein 30%).

Feed Preparation

Table 1: Research design

Code	C	HEK	HE	HK
Feed Treatment	Commercial feed	Hormone, Vitamin E and Curcumin	Hormone and Vitamin E	Hormone and Curcumin
Code	**EK**	**E**	**K**	**H**
Feed Treatment	Vitamin E and Curcumin	Vitamin E	Curcumin	Hormone

PMSG hormone and anti-dopamine mix was obtained by mixing in Fish Reproduction and Genetica Laboratorium, BDP Departement, FPIK IPB. Vitamin E used was *Quali®-E* commercial product from *Royal DSM* (Netherland). Curcumin powder was obtained from Research Institute for Spices and Medicinal Plants (BALITTRO), Bogor, Indonesia. Commercial pellet feed (protein 30%) were mixed with each materials for each treatment using white eggs 5% as binder, presented in Table 1.

Feeding treatment and rearing

This research conducted on dry season, June–August 2017. Fish were reared in net cage 3 x2 × 0.7 m3 on a soil-based pond. Mixed-feed were given 3% from fish body weight twice a day for 12 weeks. Water quality (Temperature, pH, DO, and TAN) maintained according to National Standard of Indonesia (SNI) for rearing stripped catfish [13].

Body weight, blood, gonad and liver sampling

Fish body weight were measured on 0, 2, 4, 6, 8, 10, and 12 week after feeding treatment. Fish blood also collected from three fish for hormone analysis. Blood were collected into 1.5 mL microcentrifuge tube using syringe treated with anticoagulant (38 gr/L sodium citrate) from caudal vena. Blood were centrifuged 6000 rpm for five minutes and were stored at 20°C until analyzed.

Gonad and liver were sampled at 0, 6, and 12 week after feeding treatment for histology analysis, hepatosomatic (HSI) and gonadosomatic (GSI) index measurement. Gonad and liver were collected from five fish and stored in FAA (formaldehyde: alcohol: acetic acid, 6:3:1) fixative solution. Fish gonad were stained with hematoxylin and eosin solution for histology analysis.

Fish maturation and egg diameter

Fish gonad maturation was observed by cannulation every two weeks for all fish in each treatment and five mature fish were stripped to collect the eggs. Egg diameter (n=100 for each treatment) were measured under microscope using *Image J* software (National Institute of Health, USA).

Testosterone and estradiol concentration

Blood for analysis were pooled from 3 fish. Testosterone and estradiol concentration were measured on 450 nm wave length by *Enzyme-linked immune-absorbent assay* (ELISA) method using commercial kit for testosterone and estradiol hormone (DRG international, USA; catalog number EIA 2693 and EIA 1559).

Results and Discussion

Fish body weight

After 12 weeks of rearing, fish body weight was increased but not significantly different at each week (p>0.05), presented in Table 2. Combination of Vitamin E and curcumin in feed had the lowest body weight among all treatments.

Table 2: Body weight of *P. hypophthalmus* after 12 weeks of feeding treatment

Treatment	Week 0	Week 2	Week 4	Week 6	Week 8	Week 10	Week 12
C	2,169±0,278^{a}	2,454±0,34^{a}	2,565±0,391^{a}	2,861±0,644^{a}	2,574±0,582^{a}	2,687±0,577^{a}	2,364±0,563^{ab}
HEK	1,912±0,318^{a}	2,168±0,347^{ab}	2,304±0,402^{a}	2,394±0,476^{ab}	2,45±0,475^{ab}	2,531±0,44^{ab}	2,457±0,464^{a}
HE	1,956±0,396^{a}	2,264±0,468^{ab}	2,325±0,519^{a}	2,588±0,65^{ab}	2,276±0,653^{ab}	2,547±0,584^{ab}	2,256±0,469^{ab}
HK	1,976±0,4^{a}	2,204±0,338^{ab}	2,262±0,373^{a}	2,372±0,399^{ab}	2,176±0,349^{ab}	2,381±0,417^{ab}	2,243±0,388^{ab}
EK	1,936±0,359^{a}	2,064±0,467^{b}	2,333±0,585^{a}	2,183±0,318^{b}	2,028±0,343^{b}	2,067±0,394^{b}	1,818±0,204^{a}
E	1,972±0,291^{a}	2,184±0,409^{ab}	2,344±0,463^{a}	2,447±0,5^{ab}	2,4±0,568^{ab}	2,447±0,543^{ab}	2,307±0,602^{ab}
K	1,904±0,395^{a}	2,184±0,364^{ab}	2,196±0,393^{a}	2,345±0,379^{b}	2,25±0,433^{ab}	2,389±0,423^{ab}	2,347±0,386^{ab}
H	1,978±0,365^{a}	2,304±0,494^{ab}	2,518±0,597^{a}	2,459±0,485^{ab}	2,212±0,438^{ab}	2,431±0,522^{ab}	2,267±0,528^{ab}

Feeding treatment: C= commercial feed; HEK= hormone mix, Vit. E, and curcumin; HE= hormone mix and Vit. E; HK= hormone mix and curcumin; EK= Vit. E and curcumin; E= Vit. E; K= curcumin; H= hormone mix. Different letters indicate significant difference in the same rearing week (p<0.05). Data are mean + SD (n=4).

Gonadosomatic index and Hepatosomatic index (GSI and HSI)

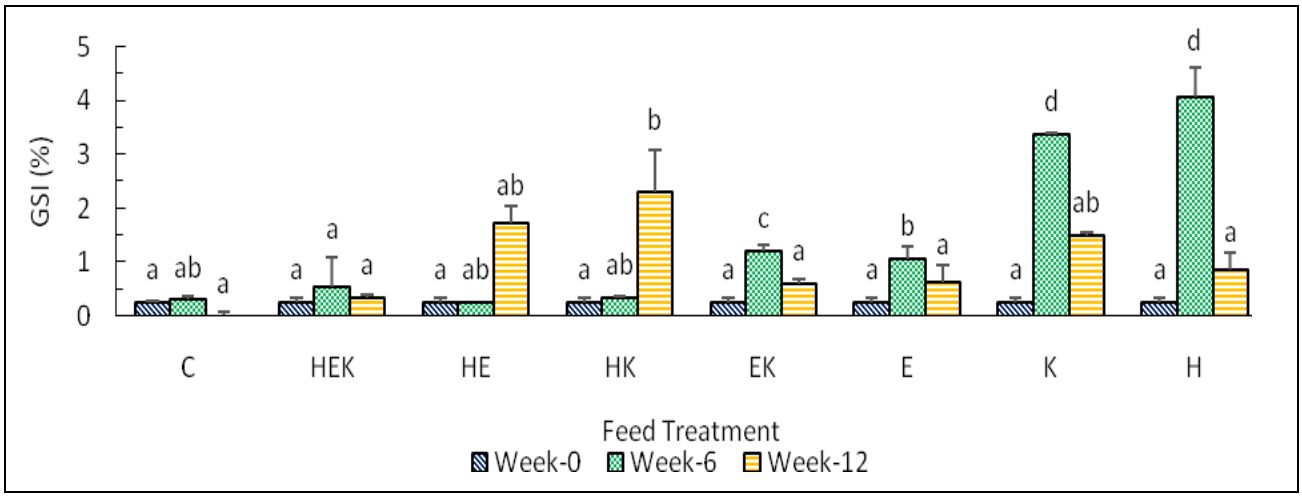

Fig 1: Fish gonadosomatic index (GSI) after 12 weeks of feeding treatments. Feeding treatment: C= commercial feed; HEK= hormone mix, Vit. E, and curcumin; HE= hormone mix and Vit. E; HK= hormone mix and curcumin; EK= Vit. E and curcumin; E= Vit. E; K= curcumin; H= hormone mix. Different letters indicate significant difference in the same rearing week (p<0.05). Data are mean + SD (n=4)

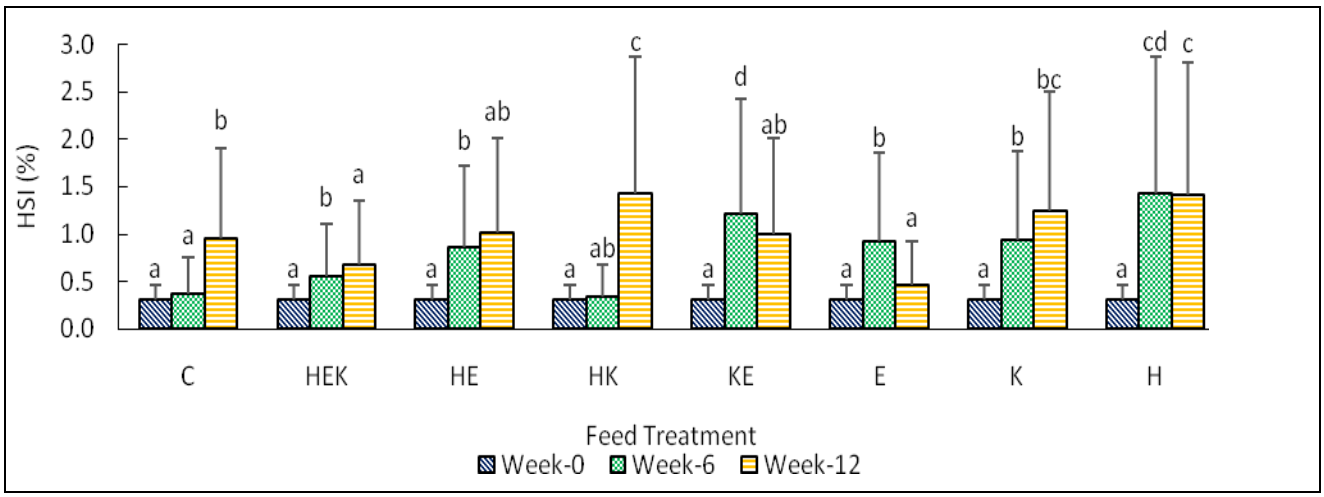

Fig 2: Fish hepatosomatic index (HSI) after 12 weeks of feeding treatments. Feeding treatment: C= commercial feed; HEK= hormone mix, Vit. E, and curcumin; HE= hormone mix and Vit. E; HK= hormone mix and curcumin; EK= Vit. E and curcumin; E= Vit. E; K= curcumin; H= hormone mix. Different letters indicate significant difference in the same rearing week (p=0.05). Data are mean + SD (n=4)

Egg Diameter

At the first week no egg was observed after stripping, since all the fish used were virgin. The eggs mostly could be stripped and observed from week-2, except for control treatment that started from the third week. Control eggs tend to be smaller than other treatments in the beginning and reach is largest diameters on the week-6. Largest diameter was obtained on KE and H treatments at week-5. (Fig 3)

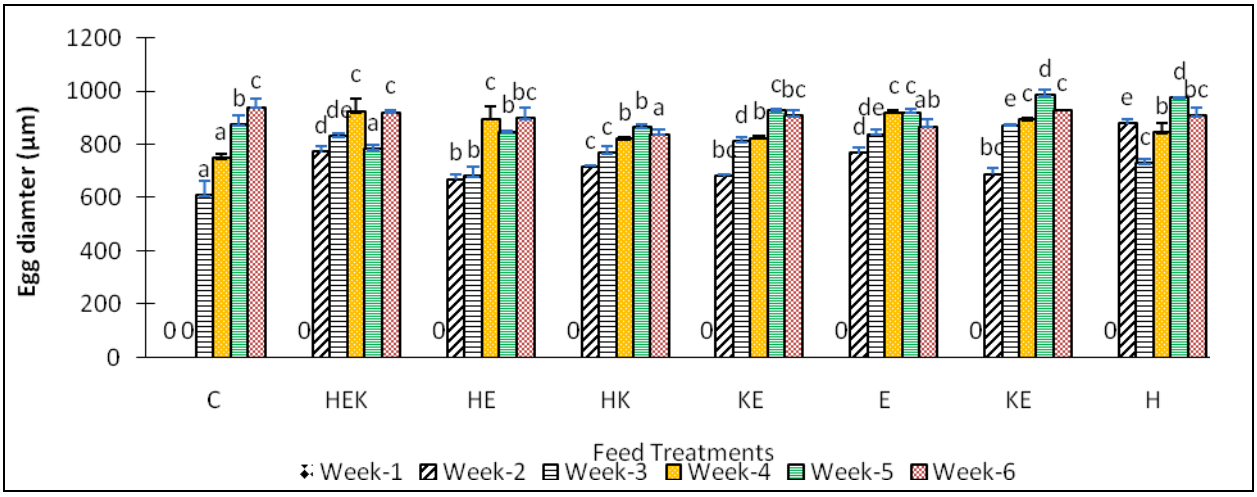

Fig 3: Fish egg diameters. Feeding treatment: C= commercial feed; HEK= hormone mix, Vit. E, and curcumin; HE= hormone mix and Vit. E; HK= hormone mix and curcumin; EK= Vit. E and curcumin; E= Vit. E; K= curcumin; H= hormone mix. Different letters indicate significant difference among treatments in the same rearing week (p<0.05). Data are mean + SD (n=100).

Testosterone and Estradiol Concentration

Testosterone concentration varied between treatments (Fig 4.) Estradiol concentration of hormone mix and curcumin combination treatment had three peaks, on week-2, 6, and 10. Highest estradiol concentration observed in control and hormone mix treatment at week-12 (Fig 5.).

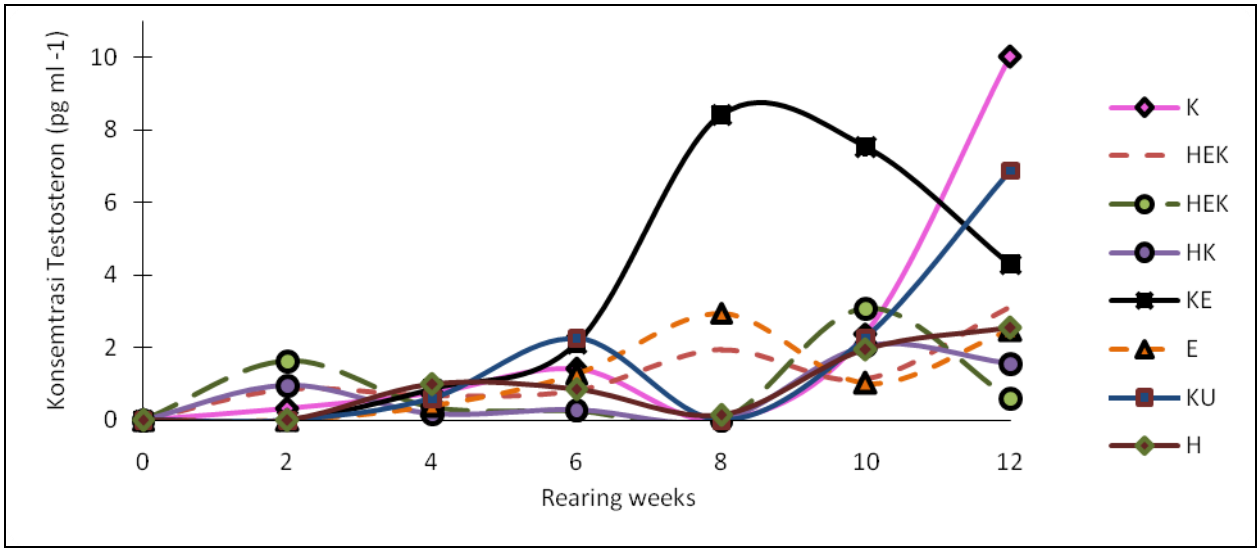

Fig 4: Fish testosterone concentration after 12 weeks of feeding treatment. C= commercial feed; HEK= hormone mix, Vit. E, and curcumin; HE= hormone mix and Vit. E; HK= hormone mix and curcumin; EK= Vit. E and curcumin; E= Vit. E; K= curcumin; H= hormone mix.

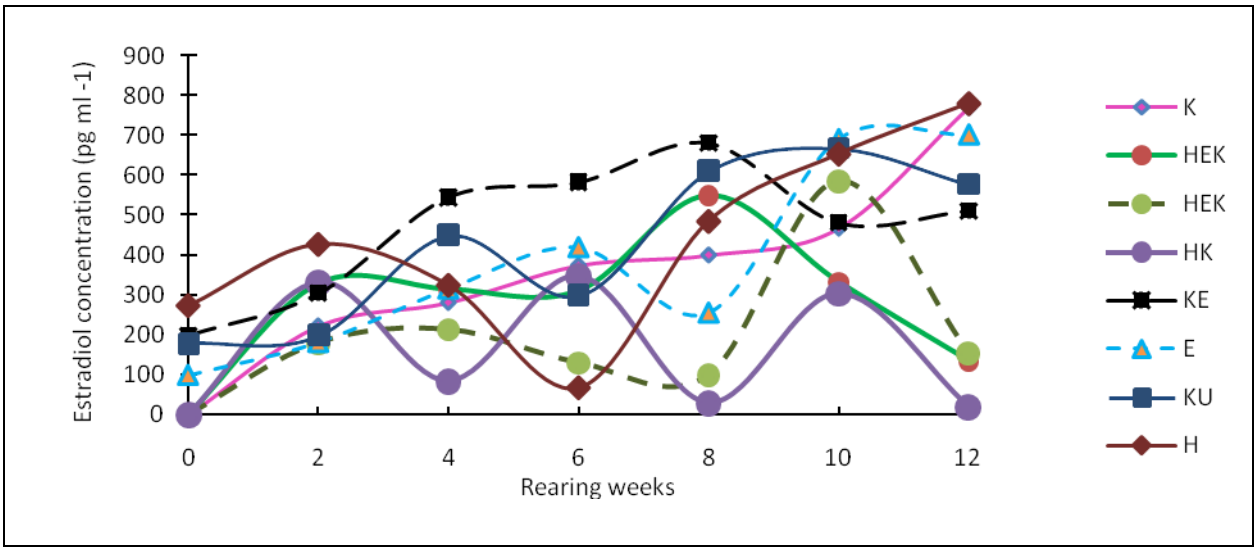

Fig 5: Fish estradiol concentration after 12 weeks of feeding treatment. C= commercial feed; HEK= hormone mix, Vit. E, and curcumin; HE= hormone mix and Vit. E; HK= hormone mix and curcumin; EK= Vit. E and curcumin; E= Vit. E; K= curcumin; H= hormone mix.

Gonad Development

Fish gonads were developed based on the histology analysis form each treatment during 12 weeks of rearing (Fig 6.). On the first week of feeding treatment, gonad from all treatments were all on the same development stages. On week-6, vitelogenesis stage was observed in several treatments. Secondary yolk globules were formed at HEK and HK treatments. Some of the egg nucleus from Vitamin E and Hormone mix treatments were migrated (migratory nucleus). On week-12, over-hydration were observed in control and hormone mix treatments.

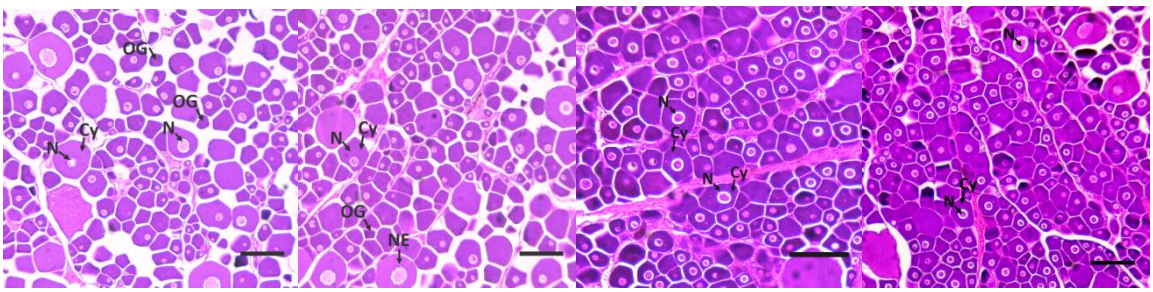

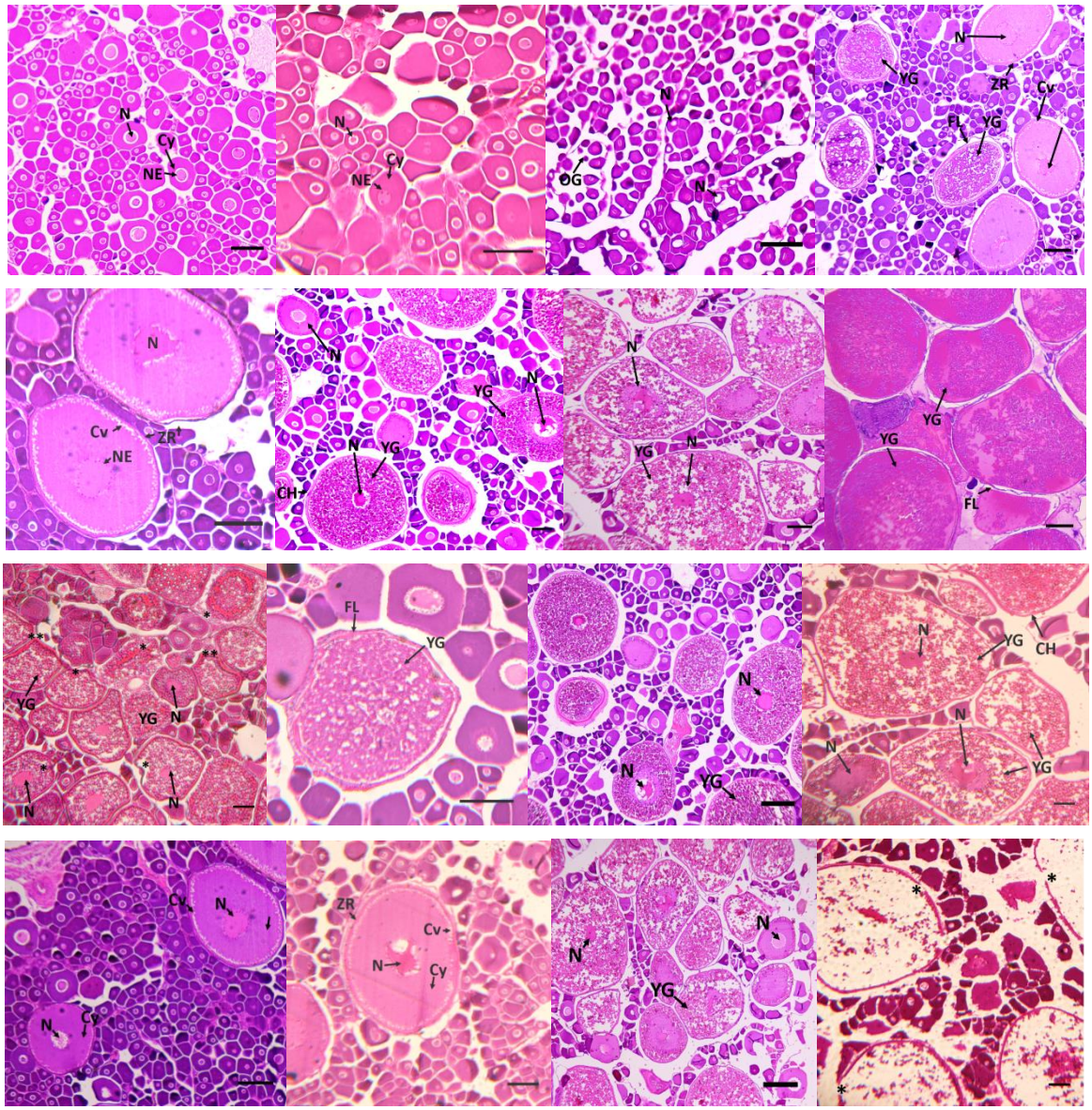

Fig 6: Ovarian histology result of *P. hypophthalmus.* C= commercial feed; HEK= hormone mix, Vit. E, and curcumin; HE= hormone mix and Vit. E; HK= hormone mix and curcumin; EK= Vit. E and curcumin; E= Vit. E; K= curcumin; H= hormone mix. N= nucleus; Cy= cytoplasm; Cv= Cortical vesicle; YG= Yolk globule; FL= Folicle layer; CH= chorion; ZR= zona radiate; abnormal (at) cells. Observed using microscope with 40 × 10 magnification. Scale bar represent 50 µm

Discussion

According to parameters measurement, especially temperature during experiment, higher temperature range (31.4–34.9 °C) compared with normal temperature (27–28 °C). Potentially, caused physiological changes on striped catfish *Pangasionodon hypophthalmus* broodstoock. It caused the changes condition in fish. In addition, changes in rainfall data from the year 2013–2015 [1] cause an extreme weather/climate changes. It caused broodstocks were difficult for maturing gonads. In this study it is known that the growth rate of EK treatment is lower than control, showed that the EK combination has a negative impact on growth and gonadal maturation. From the results of research that has been done by using three materials were able to accelerate gonad maturation in catfish during the dry season, depending on the combination of materials that used.

During this study, the control of broodstock mice gonad were observed for 12 weeks. The observed effect of hormone, vitamin E, and turmeric can stimulate the maturation of catfish gonad on testosterone concentration with 17-ß estradiol synthesis and also the role of aromatase enzyme that stimulates the process of vitellogenesis. Gonad matures normally for three months if adequate feeding is provided [18]. The treatment of HEKu (hormone + vitamin E + turmeric) showed mature gonad of catfish once in every two weeks as it (PMSG + antidopamine) is reported that may accelerate gonad maturity [8]. The addition of turmeric may increase gonadal maturation in catfish [4]. Treatment of HE (hormone + vitamin E) showed gonad maturation occurs for 2.5 months. In HKu (hormone + turmeric) it is seen that there are three peaks of 17-ß hormone estradiol concentration, i.e at 2nd, 6th, and 10th weeks or maturation of gonads once a month. The treatment of HKu is effective in the process of gonadal maturation.

Turmeric flour containing curcuma served as an antioxidant and played a role in the improvement of body cells, such as the liver and oviduct [10]. In Eku (vitamin E + turmeric) treatment showed slow gonadal development as in K (control), suspected it had a negative impact on the growth and maturation of catfish's gonads. In vitamin E showed that gonad more quickly matures because of the role of vitamin E as an antioxidant that served to prevent the process of

polyunsaturated fatty acid, phospholipid, and cholesterol in the cell wall [9]. Turmeric gave the maturity of gonad twice after three months, suspected it associated with curcuma in turmeric that served as an antioxidant and hepatoprotector to improve liver performance and nutrient metabolism used as an ingredient of egg yolks for follicular development [15]. In hormon (PMSG + antidopamine hormones), the presence of combination of gonadal maturation occurred twice that PMSG containing more FSH hormones playing a significant role in the process of vitellogenesis and gonadal maturation [2].

Histologically, the combination of hormones (PMSG + antidopamine) + vitamin E + turmeric have seen that most oocytes had GVBD and some were still undergoing previtellogenic process, and in the sixth week there was a second maturation. While on the combination of vitamin E + turmeric have seen most experienced a previtellogenic growth phase. Hormone (H) and turmeric (Ku) treatments accelerated gonad maturity with a relatively larger maximum size. At three times mature treatment of gonad within three months was thought to be due to a positive effect by the influence of hormone combinations (PMSG + antidopamine). This effect can accelerate gonad maturation along with turmeric to improve liver performance against oocyte development. In the treatment of hormones (PMSG + antidopamine) showed that most of the oocytes had atresia at week 12 because of treatment H progressed faster than other treatments.

Furthermore, after reaching the peak of the vitellogenesis process, vitellogenin levels are absorbed selectively and carried through the blood vessels then stored as oocytes in the gonads [4]. The absorption of vitellogenin by the oocytes was accompanied by the development of egg diameter. In week 12, HE (hormone + vitamin E) was the highest due to the influence of hormones (PMSG + Antidopamine) accelerated the process of vitellogenesis and added vitamin E as an antioxidant as to be more effective [16]. The combination of HEKu treatment (hormone + vitamin E + turmeric) and HKu (hormone + turmeric) can increase the value of GSI. In this study, the highest GSI values obtained in H and Ku treatment, suspected from each of them worked maximally. The combination of HKU treatments more effectively than other treatments is thought to be the effect of (PMSG + Antidopamine) and turmeric containing (antioxidant + hepatoprotector) so that the broodstocks could mature the gonads three times during the research.

Conclusion

This study conclude that the combination of (PMSG + anti dopamine) with curcumin in feed could accelerate fish gonadal maturation three times than control treatments, increased concentrations of estradiol and improved liver performance, and it could be negative impact to gonadal catfish parent growth and maturation.

References

1. Badan Pusat Statistik. Curah Hujan di Indonesia Tahun 2013–2015. Jakarta (ID): Badan Pusat Statistik, 2015.
2. Basuki F. Optimalisasi Pematangan Oosit dan Ovulasi pada Ikan Mas Koki (*Carassius auratus*) melalui Penggunaan Inhibitor Aromatase. [disertasi]. Bogor (ID): Institut Pertanian Bogor, 20O7.
3. Dewi CD. Khasiat Tepung Kunyit (*Curcuma Longa*) dalam Pakan untuk Peningkatan Performa Reprduksi Ikan Patin Siam (*Pangasionodon Hypophthalmus*) [tesis]. Bogor (ID) : Institut Pertanian Bogor, 2015.
4. Donaldson EM, Hunter GA. Induced Final Maturation, Ovulation, and Spermiation in Cultured Fishes. In: Hoar WS, Randall DJ, Donaldson EM. (Eds). Fish Physiology. Academic Press, Orlando, FL, 1983, 351-403.
5. Ferchaud S, Guiollouet P, Swarts H, Pere K, Driancourt MA. Fertility and Prolificacy Following Ovulation Induction (by PG600 or HCG) and A Single Fixed-Time AI. 21st International Pig Veterinary Society (IPVS) Congress 2010, Vancouver, 2010.
6. Kementrian Kelautan dan Perikanan. Tingkat Konsumsi Ikan. Jakarta (ID): Sistem Informasi Diseminasi Data Stasiststik Kelautan dan Perikanan, 2014.
7. Mokoginta, Syahrizal M, Zairin MJr. Pengaruh kadar vitamin E (α-*TOCOPHEROL*) pakan terhadap kadar lemak, asam lemak esensial telur, dan derajad tetas telur ikan lele *Clarias batrachus* Linn. Jurnal Akuakultur Indonesia. 2002; 1:75-59.
8. Nugraha AD. Induksi pematangan gonad ikan patin siam *Pangasianodon hypophthalmus* secara hormonal menggunakan OODEV melalui pakan. [skripsi]. Bogor (ID): Institut Pertanian Bogor, 2014.
9. Packer L. Protective role of vitame E in biological syetem. The American Journal Clinical Nutrition, 1991, 53.
10. Pangkalan I. Health Secret of Tumerseric (*Kunyit*). Jakarta (ID): Gramedia Pustaka Utama, 2011.
11. Sharaf SM. Effect of gnRH, pimozide and ovaprime on ovulation and plasma sex steroid hormones in African catfish *Clarias gariepiunus*. *Journal Animal Production and Fish.* Resource Dept, Faculty of Agriculture, Suez Canal University, Egypt, 2011.
12. Somchit NM, Shukriyah NMH, Bustamam AA, Zuraini A. Antipyretic and Analgesic Activity of Zingiber zerumbet. International Journal of Pharmacology, 2005; 01:277-280.
13. Standar Nasional Indonesia. Pengelolaan Kualitas yang Digunakan Selama Proses Budidaya untuk Ikan Patin (*Pangsianodon hypopthalmus*). Jakarta (ID): BSN, 2009.
14. Sularto. Pengaruh implantasi LHRH dan estradiol-17β terhadap perkembangan gonad ikan pangasius djambal. [tesis]. Bogor (ID): Institut Pertanian Bogor, 2002.
15. Suprijatna E, Natawihardiah D. Pertumbuhan Organ Reproduksi Ayam Ras Petelur dan Dampaknya terhadap Performa dan Produksi Telur Akibat Pemberian Ransum dengan Taraf Protein Berbeda saat Periode Pertumbuhan. Jurnal Ilmu Ternak dan Veteriner. 2005; 10:260-267.
16. Watanabe T, Kiron V. Red sea bream (*Pagrus major*). In: Bromage, N.R., Roberts, R.J. (Eds). *Broodstock* Management and Egg and Larval Quality. Blackwell Science, Oxford, 1995, 398-413.
17. Yaron. Endocrine control of gamtetogenesis and spawning induction in the carp. Aquaculture. 1995; 129:49-73.
18. Yilmaz E, Cek S, Mazlum Y. The Effects of combined phytoestrogen administration on growth performace, sex differentiation and body composition of sharptooth catfish *Clarias gariepinus* (Burchell, 1822). Turkish Journal of Fisheries and Aquatic Sciences. 2009; 9:33-37.
19. Yulfiperius, Mokoginta I, Jusadi D. Pengaruh kadar vitamin E dalam pakan terhadap kualitas telur ikan patin (*Pangasius hypophthalmus*). Jurnal Iktiologi Indonesia. 2003; 3:11-18.
20. Zairin M. Endokrinologi dan Perannya Bagi Masa Depan Perikanan Indonesia. Bogor (ID): Institut Pertanian Bogor, 2003.