



International Journal of Fisheries and Aquatic Studies

E-ISSN: 2347-5129

P-ISSN: 2394-0506

(ICV-Poland) Impact Value: 5.62

(GIF) Impact Factor: 0.549

IJFAS 2018; 6(4): 87-91

© 2018 IJFAS

www.fisheriesjournal.com

Received: 15-05-2018

Accepted: 18-06-2018

Arya PD

Research scholar, Post Graduate
Research Department of
Zoology, St. Alberts College,
Ernakulam, Kochi, Kerala, India

Binitha RN

Associate Professor, Mar
Athanasius College,
Kothamangalam, Kerala, India

Sewage Effluents of Kuroor Stream as a Concern for the Gonadal and Hepatic Histopathological Damage in a Fresh Water Fish *Oreochromis Mossambicus*

Arya PD and Binitha RN

Abstract

Water pollution induces histopathological changes in different internal organs of fish and other water organisms. As an indicator of exposure to contaminants, histology represents a useful tool to assess the degree of pollution, particularly for sub-lethal and chronic effects. Here an attempt has been done to evaluate the histological damages induced by the sewage effluents in Kuroor stream in the liver and gonads of fish *Oreochromis mossambicus*. The Kuroor stream is a natural drinking water source of the Kothamangalam municipality, Kerala, India. The stream is highly polluted due to in flow of solid and liquid waste (SLW) and is found to be non potable. To study the direct effect of sewage effluents adult fish were collected from the study site and brought to the laboratory and anaesthetized. The liver and gonads were dissected out for histological examination. To study the indirect effect of sewage effluents the fish acclimatized in the laboratory were exposed to the polluted water of the Kuroor stream for various time periods. The histological studies showed that the fish caught from study site showed disrupted hepatocytes, vacuolation and pyknotic nuclei. In gonads the testis consists of low sperm count, increased interstitial fibrosis, in ovaries follicular margin disturbed, reduced secondary oocyte etc. The fishes exposed to polluted water the liver consists of disarray of hepatic chords, cytoplasm vacuulations, and pyknotic nuclei. In gonads the testis shows decrease in size and number of interstitial cells, spermatocytes and spermatozoa were rarely observed.

Keywords: Hepatocytes, hepatic chords, histopathology, interstitial fibrosis, pyknotic nuclei, sewage effluents, solid and liquid waste

1. Introduction

Water pollution is the contamination of water bodies (e.g. lakes, rivers, oceans, aquifers and groundwater). Water pollution occurs when pollutants are directly or indirectly discharged into water bodies without adequate treatment to remove harmful compounds. Water pollution affects plants and organisms living in these bodies of water [1]. In almost all cases the effect is damaging not only to individual species and populations, but also to the natural biological communities. Sewage is the natural or manmade waste matter from homes and factories which flows away through sewers. The physical infrastructures, including pipes, pumps, screens, channels etc. used to convey sewage from its origin to the point of eventual treatment or disposal.

In some urban areas, sewage is carried separately in sanitary sewers and run off from streets is carried in storm drains. Access to either of these is typically through a manhole. During high precipitation periods a sanitary sewer overflow can occur, forcing untreated sewage to flow back into the environment. This can pose a serious threat to public health and the surrounding environment.

At many places in India, even the ground water is contaminated due to seepage from industrial, agricultural and municipal wastes and effluents. Sewage channels and agricultural runoff are also responsible for groundwater contamination.

Alterations in the aquatic environment affect the organisms that living in the water, especially fish [2]. Environmental problems with estrogenic compounds affect the aquatic environment and aquatic organisms, like feminization of male fish [3]. The natural resources of water are polluted with a variety of solid and liquid wastes. Every waste is ultimately dumped or emptied in natural water bodies [4]. Contamination of water can result from both industrial and agricultural sources.

Correspondence

Arya PD

Research scholar, Post Graduate
Research Department of
Zoology, St. Alberts College,
Ernakulam, Kochi, Kerala, India

Deficiencies in the treatment of wastewater, the disposal of untreated sewage, and inadequate operation and maintenance of treatment plants result in health risks [5]. The disposal of the untreated sewage is harmful concerning its possible hygienic and aesthetical effects and its impact on fauna and flora in the aquatic environment [6]. Sewage contains high levels of biochemical oxygen demand (BODs) and nitrogenous compounds. Ammonia and nitrite, in particular, are serious toxicants to fish [7]. In addition, the sewage effluents with their microbial and non-organic heavy metal contents represent the most dangerous chemical source of pollution for fish [8]. When aquatic ecosystems are constantly suffering the discharges of effluents produced by human activities, fish may be subjected to polluted waters which can lead to different changes ranging from biochemical alterations in single cells up to changes in whole populations [9]. Fish can be used as a monitoring tool for the quality of the aquatic environment and fish histopathology, with a broad range of causes, is increasingly being used as indicator of environmental stress since it provides a definitive biological end-point of historical exposure [10]. Histological changes appear as medium-term responses to sub lethal stress, considering their intermediate location with regard to the level of biological organization, and histology represents a rapid method to detect effects of stressors, especially chronic ones, in various tissues. Histopathological studies have been conducted to establish causal relationships between contaminant exposure and various biological responses, as it is a rapid tool to detect effects of these irritants in various organs and organ systems in fish [11].

The present study is to evaluate the histological damages caused by the sewage effluents in Kuroor stream in the liver and gonads of fish *Oreochromis mossambicus*.

2. Materials and Methods

The present study investigated the extent of pollution in terms of physicochemical parameters in a fresh water stream, Kuroor stream at Kothamangalam municipality in Kerala, India. The Kuroor Stream is a natural drinking water source of the Kothamangalam municipality in Ernakulam District of Kerala. It joins to river Muvattupuzha and forms a major drinking water source. The stream is highly polluted due to the inflow of solid and liquid waste (SLW) and is found to be non potable.

2.1 Test animal

Fishes are reported as good to study aquatic pollution because they are water inhabitants. *Oreochromis mossambicus* is abundantly seen in the kuroor stream, this is one of the few fish that survive in the area. So it is used as an experimental model.

2.2 Experimental procedure

To study the direct effect of sewage effluents adult healthy fish were collected from the study site brought to the laboratory. The liver and gonads dissected out were fixing in 10% formalin and used for the histological analysis. Sewage effluents from Kuroor stream was collected in large polythene containers and brought to the laboratory. The fish already acclimatized in the laboratory having uniform size and weight (100g) were divided in to two groups of ten each and kept in separate aquarium tanks under natural photoperiod. Fish in group one is exposed to the sewage effluents for 60 days. The second group observed as control and kept in normal water.

The fish were fed *ad libitum* every day with 40% protein feed. Fish were sacrificed after anaesthesia. Liver and gonads were fixed in 10% formalin for the histological studies.

2.3 Histopathological analysis

After fixation in 10% formaldehyde for 48 hours, The tissue were passed through alcohol series 50 to 100 % for dehydration and finally cleared in xylene. Tissues then impregnated with paraffin wax (58°) and were embedded. After embedding, blocks carried for sectioning. Sections were cut at 4 µm in thickness in a rotary microtome (Leica, Germany), sections were spread on clean glass slides coated with Mayer's albumin.

The sections were stained with Haematoxylin and Eosin as counter stain. The stained slides were rendered transparent with xylene and mounted in D.P.X. The stained sections from both ends as well as from the mid part of the tissues were observed under a research microscope (Leica Germany) attached with digital camera. Appropriate sections and portions of tissues were photographed for the purpose of description and comparison using Leica image analyser software. A minimum of 10 representative sections were analysed.

3. Results and Discussion

3.1 Liver

Histological examination revealed that control liver of *Oreochromis mossambicus* composed of mass of large hexagonal hepatic cells with cord like formations. The cords were arranged around tributaries of hepatic vein. The liver cells were large in size polygonal in shape with homogenous eosinophilic cytoplasm. Each cell contains a centrally located distinct nuclear cytoplasm contains granular deposits, sometimes with mild vacuolation, large number of blood vessels and intercellular bile canaliculi were scattered among the hepatic cords. Hepato pancreatic cells in the liver are seen to surround the hepatic portal vein as darkly stained large cells. Melano macrophage centers were sometimes found with or without associated with the hepatopancreatic centres.

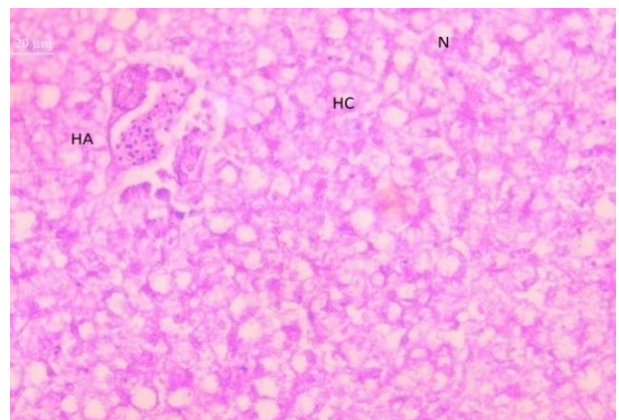


Fig 1: Micro photograph showing liver of the control fish.

Microphotography of liver of fish caught from study site also showed almost similar but more severe effects. Disrupted hepatocytes, vacuolations in the cytoplasm were very prominent. Appearance of pyknotic or condensed darkly stained nuclei was another important observation [14]. Appearances of pyknotic nucleus in the hepatocytes were due to the irreversible condensation of chromatin in the nucleus due to toxicity of some compounds in the effluents.

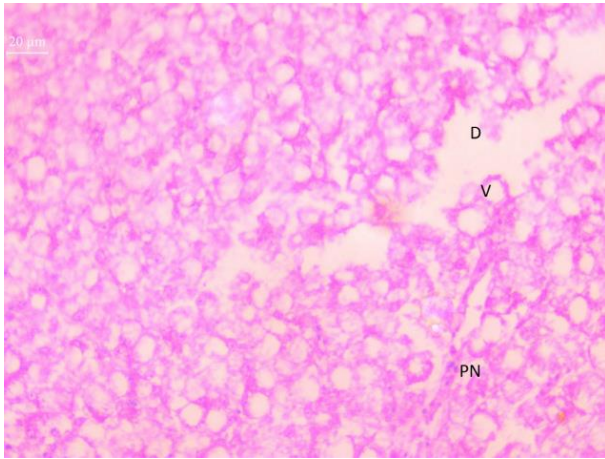


Fig 2: Microphotograph showing liver of the fish caught from study site.

Histopathology of liver of the fish after 60 days of sewage exposure showed diffuse necrosis and vacuolation and chordal arrangement of hepatocytes were markedly disrupted. Blood vessels and portal triads were scarce but more scattered than normal. Cytoplasmic valuations also observed.

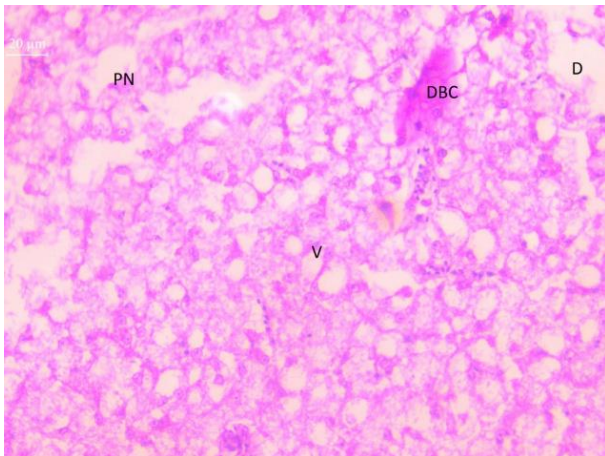


Fig 3: Microphotograph showing liver of the fish after exposure to 60 days in sewage effluents.

3.2 Testis

Water pollution has serious inhibitory effect in fish reproduction [15]. The observed histopathological alterations in the testis and ovaries in the studied fish may reduce the ability of fish to reproduce.

Histological examination revealed that control testis of *Oreochromis mossambicus* consists of large number of highly convoluted seminiferous tubules of various shapes and sizes. The inter tubular spaces contain interstitial cells. The lumens of the seminiferous tubules were filled with spermatids, occasionally contained spermatocytes and regularly organized cysts. Almost all spermatocytic stages such as spermatogonia, primary spermatocytes, secondary spermatocytes, spermatids and spermatozoa were observed. Closer to the centrally situated efferent ducts found mature spermatozoa and hypertrophied Sertoli cells were found near the efferent duct epithelium.

Haematoxylin and Eosin staining of testis of the fish collected from the polluted water revealed impairment of spermatogenesis and lobular structures [16]. The important observations were occurrence low sperm count, increased interstitial cell fibrosis [17].

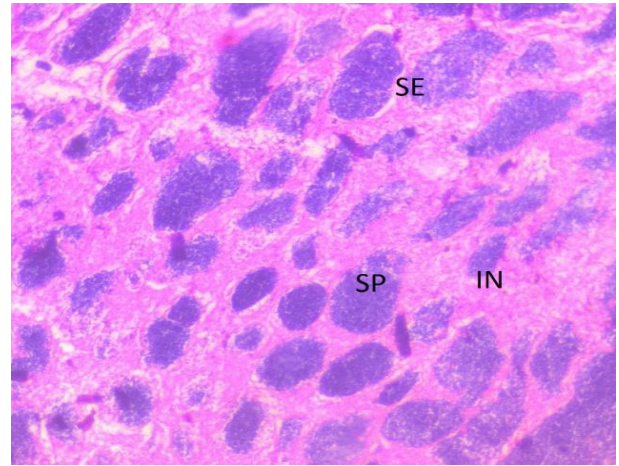


Fig 4: Microphotograph of the fish showing testis of the control fish

Fish collected from the effluent site demonstrated severe damage to testicular architecture. In majority of the observations the seminiferous tubules were completely degenerated and contained very few or no spermatozoa.

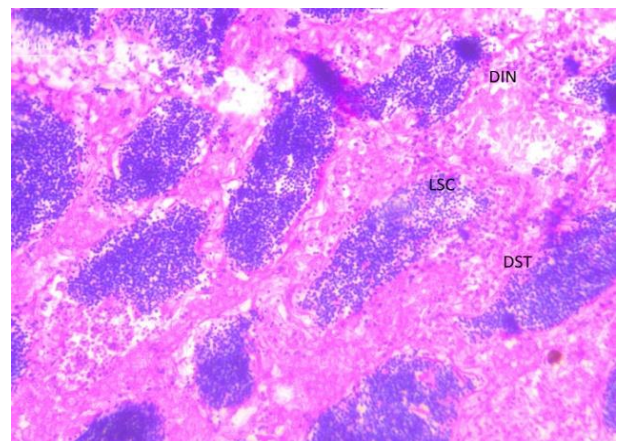


Fig 5: microphotograph showing impacts of sewage effluents in testis of the fish caught from study site

Fish exposed to sewage effluents for 60 days showed an initial stage of interstitial fibrosis, disturbed arrangement of seminiferous tubules, low sperm count, increased accumulation of fibrous tissues [18]. A decrease in size and number of interstitial cells were observed. Spermatocytes and spermatozoa were rarely observed. The sizes of the cells were reduced when compared to the control testis.

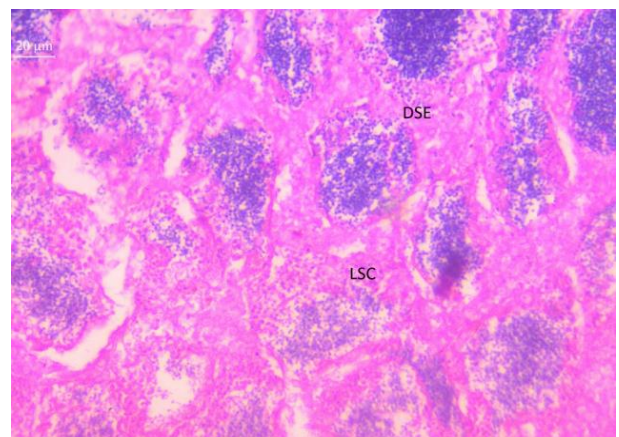


Fig 6: microphotograph showing impacts of sewage effluents in testis of the fish after 60 days of exposure.

3.3 Ovary

Exposure of fish egg to various contaminants reduced the level of fertilization [19]. The control females displayed no ovarian abnormalities at any stage of the experiments. Histological studies of the ovaries showed a number of ovigerous lamellae which are in the form of finger shaped projection, protruding in the ovarian lumen. The ovary was dominated by immature oocytes. These were characterised by small size, large nuclei and deeply stained cytoplasm. Maturing oocytes were occasionally present. They were larger in size with a large nucleus. Their cytoplasm is comparatively poorly stained.

Few degenerating Oocytes were also apparent, protruding in the ovarian lumen. The ovary was dominated by immature oocytes. These were characterised by small size, large nuclear and deeply stained cytoplasm. Maturing oocytes were occasionally present [20]. They were large in size, with a large nucleus. Their cytoplasm were comparatively poorly stained.

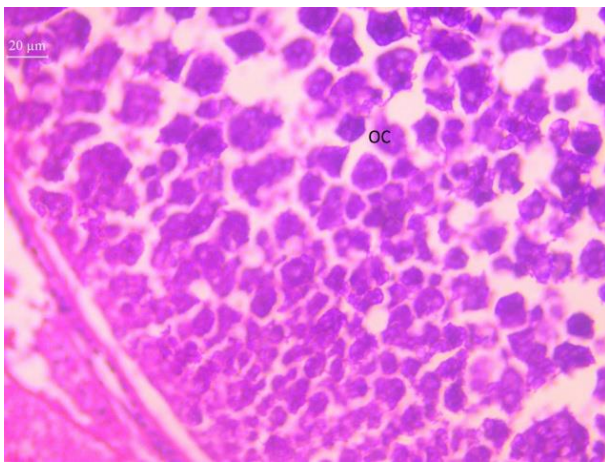


Fig 7: microphotograph of fish showing ovary of the control fish.

The fishes collected from polluted stream showed that the follicular margin was disturbed primary oocytes were damaged, the number of secondary oocytes reduced and an increasing number of fibrous tissue.

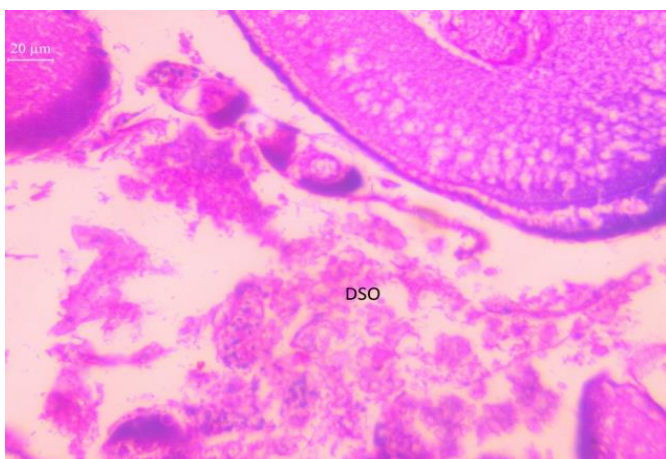


Fig 8: microphotograph showing impacts of sewage effluents in ovary of the fish caught from study site.

The fishes exposed to 30 days of polluted water showed that necrosis, hypertrophy of follicular cells and extensive vacuolation was seen in the Oocortex of young Oocytes.

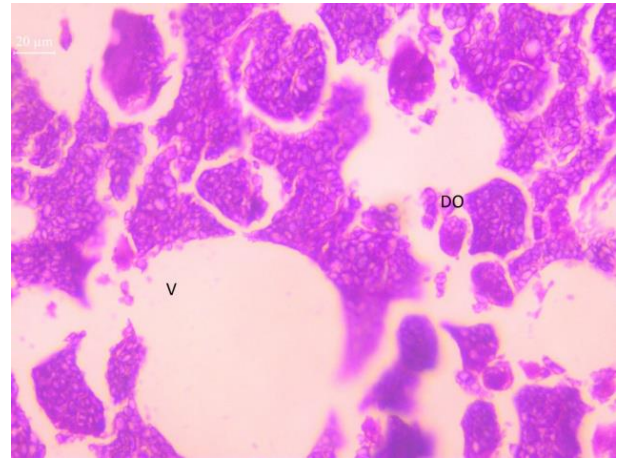


Fig 8: Microphotograph showing impacts of sewage effluents in ovary of the fish after 60 days of exposure to sewage effluents.

4. Conclusion

The present study reaches the conclusion that the water streams near the market and towns are in high risk of pollution. In case of kuroor stream were the study is conducted, it is highly polluted. The histopathological examination of liver and gonads of fish inhabiting kuroor stream showed sub lethal effect on fish and also affect their reproduction. Then the fish histopathological observation of liver and gonads of fish that exposed to the effluents for 60 days of kuroor stream shows similar effects that the fish growing in the stream. The study demonstrate the sewage effluents of Kuroor stream cause major threats to fishes and other aquatic organisms and also human beings. It also emphasize the relevance of various measures to be undertaken to rejuvenate the Kuroor stream for future generations.

5. References

- 1 Authman MM. *Oreochromis niloticus* as a biomonitor of heavy metal pollution with emphasis on potential risk and relation to some biological aspects. *Global Veterenaria*, 2000; 2(3):104-109.
- 2 Radhika V, Girija M, Rao KJ. Changes in selected biochemical parameters in the kidney and blood of fish, *Tilapia mossambica*, exposed to heptachlor. *Bull Environmental Toxicology*. 1987; 39:1006-1011.
- 3 Jobling S, Nolan M, Tyler CR, Brighty G, Sumpter JP. Widespread sexual disruption in wild fish. *J Environmental Science and Technlogy*. 1998; 32(2):498-2506.
- 4 Garg S, Gupta RK, Jain KL. Sublethal effects of heavy metals on biochemical composition and their recovery in Indian major carps. *Journal of Hazard Matter*. 2009; 163:1369-1384.
- 5 Kakuta I, Murachi S. Toxicological and Physiological response of carp, *Cyprinus carpio* exposed to raw sewage containing fish processing wastewater. *Environmental toxicology*. 1997; 12:1-9.
- 6 Bahnasawy M, Khidr A, Dheina N. Seasonal Variations of Heavy Metals Concentrations in Mullet, Mugil Cephalus and Liza Ramada (Mugilidae) from Lake Manzala. *Egypt Journal of Applied Sciences Research*. 2009; 5(7):845-852
- 7 Mahamoud SA, El-Naggar AM. Alterations in *Clarias gariepinus* caused by pollutants at El-Rahawy area,

- Rosetta branch, River Nile, Egypt. Journal of Egyptian Academic Society for Environmental Development (D-Environmental Studies). 2007; 8(2):61-70.
- 8 Silva VS, Nunes MA, Cordeiro JM, Calejo AI, Santos S, Neves P *et al.* Comparative effects of aluminum and ouabain on synaptosomal choline uptake, acetylcholine release and (Na⁺/K⁺)ATPase. Toxicology. 2007; 236:158-177.
 - 9 Stentiford GD, Feist SW. First reported cases of intersex (ovotestis) in the flatfish species dab *Limanda limanda*: Dogger Bank, North Sea. Marine Ecology Progress Series. 2005; 301:307-310.
 - 10 Bernet DH, Schmidt W, Meier P, Burkhardt-Holm Wahli T. Histopathology in fish: proposal for a protocol to assess aquatic pollution. Journal of Fish Diseases. 1999; 22(1):25-34.
 - 11 Bruslé J, González I, Anadon G. The structure and function of fish liver. In: Munshi JSD, Dutta HM. Fish Morphology. Science Publishers, 1996, 77-93.
 - 12 Hinton DE, Baumann PC, Gardner G, Hawkins WE, Hendricks JD, Murchelano RA *et al.* Biomarkers: Biochemical, Physiological and Histological Markers of Anthropogenic Stress. Lewis Publishers, Boca Raton USA, 1992, 155-196.
 - 13 Van Dyk JC, Pieterse GM, van Vuren J. Histological changes in the liver of *Oreochromis mossambicus* (Cichlidae) after exposure to cadmium and zinc. Journal of Ecotoxicology. 2007; 66:432-440.
 - 14 Roy S, Bhattacharya S. Arsenic-induced histopathology and synthesis of stress proteins in liver and kidney of *Channa punctuates*. Journal of Environmental science. 2006; 65:218-229.
 - 15 Roberts RJ. Fish Pathology. 4 ed. Blackwell Publication, UK, 2012; 1:462-465.
 - 16 Jaensson A, Scott AP, Moore A, Kylin H, Olsén KH. Effects of a pyrethroid pesticide on endocrine responses to female odours and reproductive behaviour in male parr of brown trout (*Salmo trutta* L.). Aquatic Toxicology. 2007; 81:1-9.
 - 17 Mohamed FA. Effects of phenol on the histological structures of the intestine and gonads of the freshwater teleost *Tilapia zillii* (Gervais, 1848). Egyptian. Journal of Aquatic Biology and Fisheries. 2001; 5(1):195-223.
 - 18 Amudha P, Sangeetha G, Mahalingam S. Dairy effluent induced alterations in the protein, carbohydrate and lipid metabolism of a freshwater teleost fish *Oreochromis mossambicus*. Pollution Research. 2002; 21(3):293-295.
 - 19 Banae M, Mirvaghefi AR, Ahmadi K, Ashori R. The effect of diazinon on histopathological changes of testis and ovaries of common carp (*Cyprinus carpio*). Scientific Journal of Marine Biology. 2009; 1(2):25-35.
 - 20 Moore A, Waring CP. The effects of a synthetic pyrethroid pesticide on some aspects of reproduction in Atlantic salmon (*Salmo salar* L. Aquatic Toxicology. 2001; 52:1-12.