



International Journal of Fisheries and Aquatic Studies

E-ISSN: 2347-5129

P-ISSN: 2394-0506

(ICV-Poland) Impact Value: 5.62

(GIF) Impact Factor: 0.549

IJFAS 2017; 5(5): 247-251

© 2017 IJFAS

www.fisheriesjournal.com

Received: 02-07-2017

Accepted: 03-08-2017

SPS Dutta

UGC Emeritus Fellow,

Department of Environmental
Sciences, University of Jammu,
Jammu, J & K, India

Assadullah Sheikh

UGC Emeritus Fellow,

Department of Environmental
Sciences, University of Jammu,
Jammu, J & K, India

Skeletal deformities in *Bagarius bagarius* (Ham.-Buch.) and *Crossocheilus latius diplocheilus* (Ham.- Buch.) from river Tawi, a Himalayan stream, in Udhampur area, Jammu region, J&K, India

SPS Dutta and Assadullah Sheikh

Abstract

An adult deformed *Bagarius bagarius* showing abnormal lateral curvature between pelvic fin and caudal peduncle region and *Crossocheilus latius diplocheilus* having truncated body in anal-caudal peduncle region were seen among fish collections made by fishermen in river Tawi, Udhampur area. Radiograph showed lateral flexure in vertebral column (scoliosis) in *Bagarius bagarius* and S-shaped vertebral column in *Crossocheilus latius diplocheilus*. Aberrations in these fishes inhabiting non-polluted segment of river Tawi, in Udhampur, are most probably induced by currents during development.

Keywords: Deformed fishes, non-polluted, river Tawi, Udhampur, currents

1. Introduction

There is no earlier record of deformed specimen of *Bagarius* and *Crossocheilus* genera, widely distributed in Himalayan streams, including Jammu region, in India. There is a solitary report of aberrant *Bagarius bagarius* from Nepal (Subha, 2008) ^[1]. Anomalies in fishes inhabiting Himalayan streams, though rare, have earlier been reported from Jammu region in *Barilius vagra* (Dutta, 1989-90) ^[2]; *Tortor*, *T. putitora*, *Labeo bata*, *Mystus bleekeri* and *Shizothorachthys esocinus*, (Dutta, 2012a) ^[3]; *Shizothorax richardsonii* (Dutta and Kour, 1994; Shekhar and Dutta, 1993) ^[4, 5]; *Garra lamta* (Dutta et al., 1993) ^[6]; *Labeo bata* (Dutta et al., 1996) ^[7], and *Tor putitora* and *Barilius vagra* (Kour et al., 1997) ^[8]. During fish survey in Jammu region (Dutta, et al., 2003; Dutta, 2012b; Dutta, 2015 and Dutta, 2017) ^[9, 10, 11, 12] for the last forty years, an adult abnormal specimen of *Bagarius bagarius* and *Crossocheilus latius diplocheilus* were seen for the first time among the fish samples netted by fishermen from river Tawi in Udhampur area. The objective of the present study is to identify and understand the cause of aberrations in wild fish population, which are rare in clean water bodies of Himalayas in Jammu region. Rise in percentage of fish aberrations is an indicator of water quality degradation.

2. Topography of river Tawi and Materials and Methods

Udhampur district of Jammu region is mountainous and greatly forest covered area. It is drained by river Tawi and has its origin from the laps of Kalikund glacier in Doda District. It ultimately joins the river Chenab near Marala in Pakistan. River Tawi has torrential/turbulent flow in Udhampur and in its upstream region and is joined by a large number of cold snow melt water and various spring fed streams along its length. Due to the dense forest cover springs are widely distributed in the district. A deformed specimen of *Bagarius bagarius* and *Crossocheilus latius diplocheilus* was seen among the collections made by fishermen with cast net from river Tawi in Udhampur, purchased and studied in the laboratory. These deformed and normal specimens were radiographed (Rays, India, digital x-ray machine) for skeletal analysis.

3. Results

3.1 *Bagarius bagarius* (Ham.- Buch.)

In this abnormal fish specimen, among 140 scanned specimens, measuring 28cm and weighing 350g, there is abnormal lateral body curvature between pelvic fin and caudal peduncle region

Correspondence

SPS Dutta

UGC Emeritus Fellow,

Department of Environmental
Sciences, University of Jammu,
Jammu, J & K, India

(scoliosis) and disposition of various fins (Fig-3). Longest pectoral fin ray extends the longest pelvic fin ray on left side and is normal placed on right side (falls short of pelvic fin origin). Longest pelvic fin ray extends to the middle of dorsal adipose fin on left side and origin of dorsal adipose on right side. In a normal fish there is wide space between the tip of longest pectoral fin ray and pelvic fin origin and the longest pelvic fin ray and origin of the adipose fin. Anal fin origin in normal and aberrant fish is opposite to adipose fin origin. Longest anal fin ray, however, extends caudal fin base in this deformed fish. In a normal fish there is a space between the longest anal fin ray tip and caudal fin base (Fig.1)

X-ray study has revealed 34 and 37 vertebrae in normal and aberrant *Bagarius bagarius*, respectively (Figs.2 & 4). Vertebral column is streamlined having normal neural and haemal spines, urostyle and caudal bones in a normal fish (Fig.2). In this anomalous fish there are aberration in vertebrae and vertebral column shape, neural and haemal spines, urostyle and caudal bones and are described as below: Following 1st to 18th normal vertebrae, vertebral column is aberrant (scoliosis) in which:

1. Vertebral column between 19th to 30th vertebrae forms a lateral semi circular projection (scoliosis) on left side; 20th – 22nd and 25th -28th vertebrae are short and intervertebral spaces are reduced. Neural spines in the upper side of semicircular scoliosis are invisible.
2. Posteriorly, vertebral column is normal. However, urostyle and caudal bones are not clear.

From x-ray analysis it is clear that lateral curvature between pelvic fin and caudal peduncle region in this anomalous

Bagarius bagarius is due to vertebral column scoliosis.

3.2 *Crossocheilus latius diplocheilus* (Ham.- Buch.)

This single aberrant specimen, among 200 analysed specimens of *Crossocheilus latius diplocheilus*, measuring 13cm and weighing 95g, was identified by post annal truncated body showing lateral concavity and convexity on either side (Fig.-7). In a normal streamlined fish there is a wide gap between the extension of the longest pectoral fin ray and pelvic fin origin, longest pelvic ray and anal fin origin and longest anal fin ray and caudal fin base (Fig.-5). In this aberrant fish, placement of pectoral and pelvic fin is almost like a normal fish. Longest anal fin ray, due to truncated caudal peduncle, extends beyond caudal fin base. In a normal fish dorsal fin origin is towards the snout than the caudal fin base. In this deformed fish, dorsal fin origin is towards the caudal fin base.

Radiological study has revealed 33 vertebrae, after complex vertebrae, in both normal and abnormal fish (Fig. 6 and 8). X-ray analysis has showed some aberrations in vertebral column placement and are given as below.

1. Vertebral column is normal between first twenty vertebrae
2. Posteriorly vertebral column is S- shaped. 21st to 30th vertebrae are short and intervertebral spaces reduced, Neural spines between 23rd to 30th vertebrae overlapping. Haemal spines between 21st to 31st vertebrae short and curved.
3. Urostyle and caudal bones are normal.



Fig 1: Photograph of a normal specimen of *Bagarius bagarius* (Ham.-Buch.)



Fig 2: X-ray photograph of normal specimen of *Bagarius bagarius*(Ham.-Buch.)



Fig 3: Photograph of a deformed specimen of *Bagarius bagarius* (Ham.-Buch.)

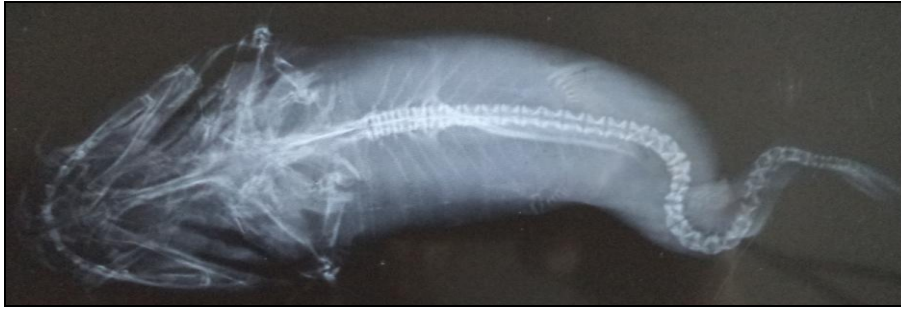

Fig 4: X-ray photograph of deformed specimen of *Bagarius bagarius*(Ham.-Buch.)



Fig 5: Photograph of a normal specimen of *Crossocheilus latius diplocheilus* (Ham.-Buch.)

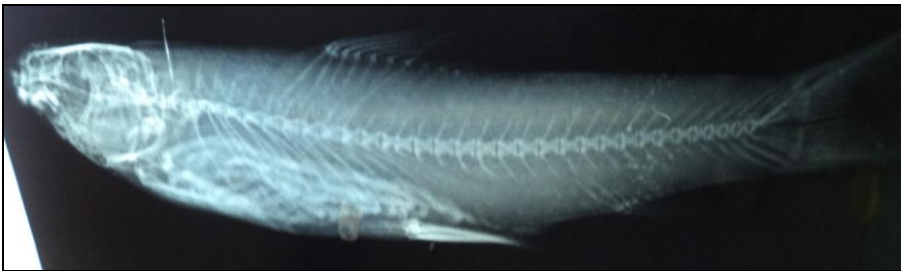


Fig 6: X-ray photograph of normal specimen of *Crossocheilus latius diplocheilus* (Ham.-Buch.)



Fig 7: Photograph of deformed specimen of *Crossocheilus latius diplocheilus* (Ham.-Buch.)

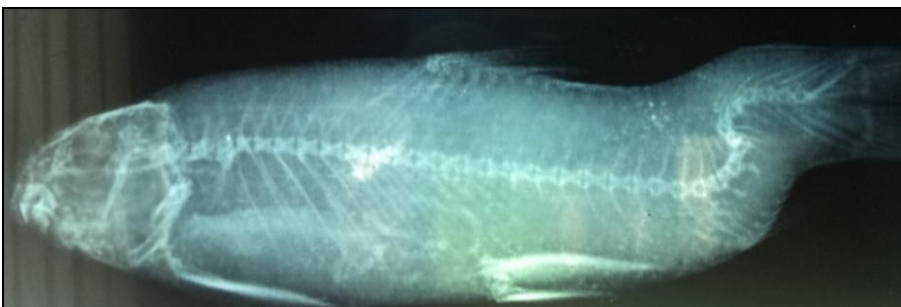

Fig 8: X-ray photograph of deformed specimen of *Crossocheilus latius diplocheilus*.

4. Discussion

Record of only one deformed specimen of *Bagarius bagarius* and *Crossocheilus latius diplocheilus*, seen among the fish collections surveyed for about last forty years, in Jammu

region, reveals rare aberrations in wild populations in these fishes. This is either because deformities in the Himalayan quality water streams are rare or there is decreased viability of deformed fishes. In fishes, in general, the caudal peduncle and

caudal fin has an important role in maneuvering and steering functions. Thus, it must be constructed so as to cope with hydrodynamic stress with the least possible expenditure of energy. Any deformity in caudal region will impair the flexibility of tail hindering the performance of the fish, including the capacity to get food and to avoid predators. Record of these two adult aberrant specimens show that these anomalies are not fatal and these fishes are able to avoid predators and feed normal.

Fish teratology in wild population has been attributed to multiple factors. Fluctuation in water temperature is considered to be one of the causes of spinal deformities (Hubbs, 1959; Al Hassan, 1982; Wang and Tsai, 2000) ^[13, 14, 15] as sudden change in water temperature may lead to abnormal muscular growth and spinal deformity. Due to optimum annual water temperature range (10-26 °C), in river Tawi, it is not possible to correlate aberrations in fishes, under discussion, to temperature fluctuations.

Vertebral anomalies due to one or other chemical parameter like salinity fluctuations, low dissolved oxygen, high free CO₂ etc. have been reported by various workers (Lee and William, 1970; Martens *et al.*, 2006; Jawad and Oktener, 2007) ^[16,17,18].

Fish anomalies have also been attributed to water pollution (Couch *et al.*, 1977; Subha, 2004; Villeneuve *et al.*, 2005; Sun *et al.*, 2009) ^[19, 20, 21, 22]

In view of a good water quality of river Tawi in Udhampur (temperature, 10-26 °C; transparency, 7-96cm; pH, 8.32-8.85; conductivity, 0.203-0.350mS; total dissolved solids, 105.66-183.1mg/l; salinity, 0.20 ppt; DO, 6.22-10.43mg/l; BOD, .70-2.1mg/l; free CO₂, nil; carbonate, 4.5-20.7mg/l; bicarbonate, 108.5-216.20mg/l; chloride, 4.22-11.19mg/l; calcium, 24.77-54.20mg/l; magnesium 469-14.9620mg/l; total hardness, 100.40-188.20mg/l; sodium, 1.3-8.9mg/l; potassium, 0.22-2.1mg/l; phosphate, 0.010-0.03mg/l; and chromium, nickel, zinc, lead and copper below detectable limits observed by (Dutta, 2012c) ^[23] and absence of any type of pollutant entry (sewage or industrial effluents) in the area of fish sampling and upstream in river Tawi, Udhampur, suggests that anomalies in these two fish specimens are not due to water degradation.

Among biological factors Schwartz (1973) ^[24] speculated that diseases such as tuberculosis and salmonellosis may be the cause of fish deformities. Needham and Wootten (1978) ^[25] noticed that myxosporidian parasites commonly invade cartilage of teleosts and could produce lesions of the spine. Kent *et al.*, (2004) ^[26] assigned various types of deformities in cyprinoid fishes to metacercariae of digenean trematode (*Apophallus spp*) and myxosporidian (*Myxobolus sp*). Villeneuve *et al.*, (2005) ^[21], have revealed in their studies that metacercariae of a digenean trematode is a primary cause of deformities in fishes inhabiting Willmette River. Yokoyama, *et al.*; (2005) ^[27] attributed vertebral aberrations (Kyphosis) in Japanese mackerel (*Scomber japonicus*) to *Myxobolus acanthogobii*. Absence of any sign of parasitic infestation in *Bagarius* and *Crossocheilus*, inhabiting river Tawi, rules out these anomalies to any disease.

A possible cause of deformities in *Bagarius bagarius* and *Crossocheilus lotius diplocheilus* is induced by water currents in fish breeding grounds in streams and is in accordance to the observations of (Dutta, 2012a; Bakiel *et al.*, 1984; Chatian, 1994; Divanach *et al.*, 1997) ^[3, 28, 29, 30].

5. Acknowledgements

UGC, New Delhi, is acknowledged for providing Emeritus Fellowship to Prof. S.P.S. Dutta. Necessary facilities provided

by Head, Department of Environmental Sciences, University of Jammu, Jammu, are gratefully acknowledged.

6. References

- Subha BR. Abnormality in *Bagarius bagarius* (Ham.) (Siluriformes: Sisoridae) from Nepal. *Our Nature*, 2008; 6:26-29.
- Dutta SPS. Vertebral deformity in *Barilius vagra* (Ham.-Buch.) from Jammu, Matsya, 1989-90; 15-16:166-68.
- Dutta SPS. Limnology of the river Chenab, at Akhnoor, Jammu. Part II Deformities in *Schizothoraichthys esocinus* (Heckel), *Tor putitora* (Ham.-Buch.) *Tor tor* (Ham.-Buch.) *Labeo rohita*, (Ham.-Buch.) and *Mystus bleekeri* (Day) Project report submitted to UGC, New Delhi. 2012a, 74.
- Dutta SPS, Kour H. Pelvic fin deformity in *Shizothorax richardsonii* (Gray and Hard) inhabiting Rajouri river, Jammu and Kashmir. *J. Fresh Water. Biol.* 1994; 6(2):165-66
- Shekhar C, Dutta SPS. An abnormal specimen of *Shizothorax richardsonii* (Gray and Hard) with vertebral deformities. *Him. J. Env. Zool.* 1993; 7:101-102.
- Dutta SPS, Sharma J, Koul V. A truncated specimen of *Garra lamta* (Ham. – Buch.). *J. Nat. Cons.* 1993; 5(2):115-16.
- Dutta SPS, Kour H, Sharma J. Occurrence of malformed specimen of *Labeo bata* (Ham.- Buch.) in river Tawi, Jammu, *J. Natcon.* 1996; 8:147-149.
- Kour H, Kaul V, Dutta SPS. Deformities in some freshwater fishes in Jammu. *J. Freshwater Biol.* 1997; 8(4):213-216.
- Dutta SPS, Kour H, Zutshi N. Ichthyofauna of river Tawi and its tributaries, an important tributary of river Chenab, J&K. *J. Aqua. Biol.* 2003; 18(2):61-68.
- Dutta SPS. Limnology of the River Chenab, at Akhnoor, Jammu. Part-I. Water quality, zooplankton and fish. Project report submitted to UGC, New Delhi. 2012b, 74.
- Dutta SPS. survey and systematic analysis of fish fauna of erstwhile Udhampur district, Jammu region, with new records of *Barilius radiolatus* Gunther, *Biota lohalthata* Chandhuri, *Botia Dario* (Ham.-Buch.) and *Glyptothorax punjabensis* Mirza and Kashmiri. *Environ. Cons. J.*, 2015; 16(3):39-47.
- Dutta SPS. Survey and systematic analysis of fish fauna of Jammu region with reference to coldwater fish. Emeritus fellow project report submitted to UGC, New Delhi. 2017, 186.
- Hubbs C. High incidence of vertebral deformity in two natural populations of fishes inhabiting warm water springs. *Ecology*, 1959; 40:154-155.
- Al-Hassan LAJ. Vertebral deformities in fishes from Iraq and United Arab Emirates, Arabian Gulf, Iraqi. *Jour. Mar. Sci.* 1982; 1(1):13-23.
- Wang LH, Tsai CL. Effects of temperature on deformity and sex differentiation of Tilapia, *Oreochromis mossambicus*. *J. Expt. Zool.* 2000; 286:534-537.
- Lee CH, William WD. Abnormality in fishes due to salinity fluctuations. *J. Fish Biol.* 1970; 2:55.
- Martens LG, Witten PE, Fivelsted S, Haystune AB, Sulvaried Vikesa V, Oback A. Impact of high water carbon dioxide on Atlantic salmon smolts (*Salmo salar* L) on fish performance, vertebral composition and structure. *Aquaculture*, 2006; 261(1): 80-86.
- Jawad LA, Oktener AO. Incidence of lordosis in the

- freshwater mullets. *Liza abu* (Heckel, 1843), collected from Ataturk dam lake, Turkey. *Anales de Biologia*, 2007; 29:105-113.
19. Couch JA, Winstead JA, Goodman LA. Kepone induced scoliosis and its biological consequences in fish. *Science*, 1977; 197:585-587.
 20. Subha BR. Anomalies in bighead carp, *Aristichthys nobilis* and African catfish, *Clarias gariepinus*, in Baratingar, Nepal. *Our Nature*. 2004; 2:41-44.
 21. Villeneuve DL, Curtis LR, Jenkins JJ, Warner KE, Tilton F, Kent ML *et al.* Environmental stresses and skeletal deformities in fish from the Willmette River, Oregon. *J. Env. Sc Tech*. 2005; 39(10):3495-350.
 22. Sun PL, Hawkins WE, Overstreet RM, Brown Peterson NJ. Morphological deformities as biomarkers in fish from contaminated rivers in Taiwan. *Int. J. Environ. Res. Public Hlth*. 2009; 6:2307-2331.
 23. Dutta SPS. Ecology of river Tawi with reference to its pollution in Jammu city. Project report submitted to the Department of Ecology, Environment and Remote sensing Govt. of Jammu and Kashmir. 2012c, 55.
 24. Schwartz FJ. Spinal and cranial deformities in the Elasmobranchians *Carcharhinus leucas*, *Squalus acanthias* and *Carcharhinus milberti*. *J. Elisha Mitchell Sci. Soc.* 1973; 89:74-77.
 25. Needham T, Wootten R. The parasitology of teleosts. In *Fish Pathology*. R.J. Roberts (Ed) Bailliere Tindall, London, England. 1978, 144-182.
 26. Kent ML, Watral VG, Whipps CM, Cunningham MF, Crisctone CD, Heidel JR *et al.* A digenean metacercaria (*Apophallus* sp) and a myxozoan (*Myxobolus* sp) associated with vertebral deformities in cyprinid fishes from the Willamette river, Oregon. *J. Aquat. Anim. Hlth.*, 2004; 16:116-29.
 27. Yokoyama H, Freeman MA, Itoch JA, Fukuda Y. Spinal curvature of cultured Japanese mackerel, *Scomber japonicus*, associated with a brain Myxosporean, *Myxobolus acanthogobii*. *Dis. Aquat. Org.* 2005; 66:1-7.
 28. Backiel T, Kokurewicz B, Ogorzalek A. High incidence of skeletal deformities in carp, *Cyprinus carpio*, reared in cages in flowing water. *Aquaculture*. 1984; 43:369-380.
 29. Chatian B. Abnormal swim bladder development and lordosis in sea bass (*Dicentrarchus labrax*) and sea bream (*Sparus auratus*). *Aquaculture*. 1994; 119:371-379.
 30. Divanach P, Papandroulakis N, Anastasiadis P, Koumoundouros G, Kentouri M. Effect of water currents on the development of skeletal deformities in seabass (*Dicentrarchus labrax* L.) with functional swimbladder during post larval and nursery phase. *Aquaculture*, 1997; 156:145-155.