ISSN: 2347-5129
(ICV-Poland) Impact Value: 5.62
(GIF) Impact Factor: 0.549
IJFAS 2016; 4(6): 314-318

www.fisheriesjournal.com
Received: 12-09-2016
Accepted: 13-10-2016

Mohamad E Nofal
General Authority of Fish Resources and Development, Manzala Farm

Viola H Zaki
Department of Fish Diseases and Management, Faculty of Veterinary Medicine, Mansoura University

Abdulla A El-Shebly
Department of Fish Breading, National Institute of Oceanography and Fisheries, Alexandria University

Correspondence
Mohamad E Nofal
General Authority of Fish Resources and Development, Manzala Farm

Implications of heavy infestation of *Lernaea cyprinacea* (Crustacea: Copepoda) of Silver carp, *Hypophthalmichthys molitrix* at Manzala area, with trial for control using Trichlorfon

Mohamad E Nofal, Viola H Zaki and Abdulla A El-Shebly

Abstract
An outbreak of heavy infestation of Crustacean parasite, *Lernaea* sp. has occurred autumn 2015 with heavy losses of cultured fish in Manzala area, Egypt. In this study, parasitological examination was done on about five hundred (500) earthen pond cultured Silver carp fingerlings, with body weight averaged (2-3 g), from intensive culture at Lake Manzala, for surveillance and detection of the infested *Lernea* sp. Clinical signs, postmortem (pm), and histopathological findings were determined. Also, the infestation rate was evaluated in relation to the physico-chemical water quality parameters. Furthermore, a trial of treatment using Trichlorfon 80% powder in a dose rate of 0.5 ppm three successive times with 10 days interval was investigated. The results revealed that (320) specimens were found to be infested with *Lernaea cyprinacea*, about (64%) of the total examined fish. Infested fish were off-food, restlessness, anemic, rubbing themselves against hard objects, accumulated at the water inlet, abnormal swimming and severe respiratory manifestation. Additionally, the infested *L. cyprinacea* was seen by naked eye remain attached to the body, fins and gills, with hemorrhagic ulcers has a button shape with elevated border were found at the point of attachment. There is no any postmortem examination. The results of water quality parameter revealed increased levels of Nitrite (0.2ppm), total ammonia (0.15ppm), H_2S (0.2 ppm), dissolved oxygen (7 mg/l) and with alkaline pH. The results also showed reduction in fish mortalities with no any detectable Lernea sp. on fish surface. It can be concluded that the infestation rate of Lerneosis was elevated with poor water quality and Trichlorfon can effectively eradicate *L. cyprinidae* from the infested fish.

Keywords: Lernaea cyprinacea, Silver carp, Lake Manzala, Trichlorfon

1. Introduction

Parasitic diseases constitute about 80% of diseases affecting warm water fish in Egypt (Eissa, 2002) [13], that mainly affect the fish health, growth and survivability (Barson and Marshall, 2003) [8]. *Lernaea* includes 70 species of parasites that affecting many aquatic animal species (McAllister *et al*., 2011) [25]. *L. cyprinacea* "Anchor worm" is an important crustacean parasite of freshwater fish that has a wide geographic range (Hoffman, 1999 & Silva-Souza *et al*., 2003) [17, 37].

Various *Lernaea* sp. parasitize on freshwater fishes and have worldwide distribution; the adult parasites are particularly harmful to young fish because of their relatively large size and mode of attachment and feeding which lead to secondary bacterial infections when it leaves the host (Piasecki *et al*., 2004) [29]. *Lernaea* sp. have 9 stages in the life cycle, including three free-living naupliar stages, five copepodid stages, and one adult stage, a male and female adult's mate on the fish host, copulation occurs during the fourth copepodid stage, when the copulation was occurred the male's presumably dying while the females metamorphose and insert the anterior region of the body into the host tissue and then produce eggs (Nagasawa *et al*., 2007) [27]. Only the adult female lernaeids are parasitic, whereas the males and immature forms of both sexes are free living. It is found on the tegument, gills, and fins and around the eyes and the buccal cavity of the fish host. The parasite has a worm-like body, with chitin growths at the anterior part of the body, through which it attaches to the host body (Yashouv, 1959) [38].

L. cyprinacea is capable of massive attacking, with high pathogenicity and mortality, mainly during the summer season. Besides the effects of penetration, hemorrhages and ulcerations are

also caused (Carnevia and Speranza, 2003) [11]. The most dangerous consequence of an intensive attack results in blood loss, increase of monocytes, secondary infections, intense lymphocytopenia and neutrophilia (Silva-Souza *et al*., 2000) [36]. The adults of *L. cyprinacea* leave large holes with round openings in the muscle and skin allow the entrance of secondary microbial infections causing death of the fish (Amina El-Mansy, 2009) [3].

The incidence of disease problems especially in intensive system fish farms is due to overcrowding and /or deteriorating water quality such as unsuitable water temperature, and pH and free ammonia concentrations (Kugel *et al*., 1990) [22]. High temperature can contribute positively in fast development of copepod, and the parasite intensity was increased with mean temperatures of 19 ˚C, suggesting that temperature only is not a major factor in the increase in parasite intensity (Barson *et al*., 2008) [9]. Highest prevalence of the parasite in the late winter December to April (water temperature 13-23ºC) and low during the summer months (Iqbal *et al*., 2012) [19], the peak season for the parasite occur in October to December (hot, wet season) (Barson *et al*., 2008) [9].

The organophosphate insecticide Trichlorfon (Kashara, 1962) [21], Formalin (Putz and Bowen, 1964) [31], Lexone (Gopalkrishan, 1964) [14] and Benzene Hexachloride (Hoffman and Meyer, 1974) [18] were listed as effective chemicals for *L. cyprinacea* control.

Our study aimed, therefore, for covering the following points; 1) determination of the relationship between the infestation of *L. cyprinacea* of Silver carp and the water quality parameters of Manzala area, 2) Evaluation of Trichlorfon for controlling their infestation.

2. Material and Methods

2.1 Fish Specimens

A total number of 500 fingerlings of Silver carp, *Hypophthalmichthys molitrix*, with body weight ranged (2-3 g), were collected a live from private fish farm at Manzala area, November 2015, during an outbreak of *Lernaea* infestation. All specimens were transported immediately on ice bag to the laboratory parasitology, department of parasitology, Faculty of Veterinary medicine, Mansoura University.

2.2 Clinical examination

Clinical examination was performed (Austin and Austin, 1987) [6], where fish were immediately examined for any external parasitological manifestation, skin darkening, presence of any cloudiness, discoloration, paleness, congestion, detached scales or fin rot, hemorrhage, redness and ulcers. Also the examination for exophthalmia or cloudiness and the abdomen was also examined for enlargement.

Post mortem examination (Amlacher, 1970) [4], where fish placed on right side and the left side was disinfected by 70% ethyl alcohol. The first cut was made in front of anus through the abdominal wall; the second cut was made perpendicular to the first directly behind to the gill cover, the third cut was made from anus to the head region parallel to the lateral line. The abdominal wall was left by forceps and the internal organs become visible and exposed for post mortem findings.

2.3 Parasitological examination

Parasitological examination of the infested Silver carp was done, whereas, the crustaceans were collected gently by using forceps on a slides, fixed by 3% formalin preserved in 70% alcohol, they are not stained but cleared in lacto phenol then mounted in polyvol (Refaat *et al*., 2000) [33].

2.4 Histopathological examination

For histopathological examination, normal and infested fish tissues were obtained from the site of attachment and immediately fixed in alcoholic Bouin's solution for 24 hrs. These specimens were dehydrated in ascending concentrations of ethyl alcohol, cleared in Xylol and embedded in paraffin wax. Vertical sections were cut at 5 to 7 microns, and stained with Harri's Haematoxylin and subsequently counter stained with eosin. Finally, the slides were microscopically examined and photographed using camera mounted on light microscope and described (Carleton *et al*., 1967) [10].

2.5 Physico-chemical examination of water samples

Water samples were collected during the outbreak, from under the water surface, in clean and dark brown coppered glass bottle. Water temperature was measured in location by using ordinary thermometer (Coche *et al*., 1998) [12]. Other parameters as dissolved oxygen (D.O) (measured by a dissolved oxygen meter), percent of water salinity (measured by a Salinometer), pH values (measured by a pH meter), and phosphorus, Nitrite, Nitrate, Hardness, alkalinity, Turbidity, water transparency, Iron, Copper and Hydrogen disulphide were measured (APHA, 1992) [5].

2.6 Field trial treatment using Trichlorfon® for control

Organophosphorus compound, Trichlorfon 80% powder (ACMA Company) at a dose rate 0.5 g / m^3 of pond water was evaluated. Reduce the level of water column about 40 cm. After calculation of the amount of powder required, each 0.5 kg of powder is dissolved in about 20 Litters of water and spread over the surface of pond water in different parts of the pond at the same direction of wind, after 3 days from treatment open the water supply again until reach the normal water level after that begin to increase the water drainage to change the water of the pond also begin to feed the fish again according to their body weight. Examine treated fish for the presence of the parasite and determined the percentage of the parasite remain alive. Repeat the same previous treatment after 10 days with the same previous precautions for about 2 weeks after the first one and take a sample of fish after treatment for parasitological examination.

3. Results and Discussion

3.1 Clinical examination

The results revealed that (320) specimens were found to be infested with *Lernaea cyprinacea*, about (64%) of the total examined fish. The infested fish were off-food, restlessness, anemic, rubbing themselves against hard objects, accumulated at the water inlet, abnormal swimming and severe respiratory manifestation. This result was agreed with Nagasawa *et al*. (2007) [27]. Additionally, the infested *L. cyprinacea* was seen by naked eye remain attached to the body (Plate 1), fins and gills, with hemorrhagic ulcers has a button shape with elevated border were found at the point of attachment. There is no any postmortem examination. It was demonstrated that the attachment point was often accompanied with distinct lesion occasionally inflamed and hemorrhagic with swollen margins, focal distribution along body surface (Carnevia and

Speranza, 2003) [11].

The infestation of *L. cyprinacea* was mainly focused in the ventral abdominal region. This was previously mentioned as the abdomen and ventral side of the body of the fish is the most common site of attachment of *Lernaea* sp.

L. cyprinicae was founded embedded in the dorsal musculature, abdominal region and the eye, by chitin portion (Yashouv, 1959) [38]. It has definite affinity for abdomen and at the base of fins. These sites offer more protection in water and further these may be more easily penetrated by the parasite, *L. cyprinacea* prefers that location which offers greater protection against water current (Medeiros and Maltchik, 1999) [26].



Plate 1: Naturally examined Silver carp showed heavy infestation of *L. cyprinacea* especially in the abdominal & dorsal region (Photo 1), and there were several female *L. cyprinacea* attached strongly in the ventral abdominal region showing their egg sacs (Photo 2).

High seasonal prevalence of *L. cyprinacea* infestation of Silver carp was in autumn; this was agreed with the previous results of several reports (Medeiros and Maltchik, 1999; Hanna, 2001; Awad, 2007; Lazar, 2009 and Saleh *et al*., 2010) [26, 16, 7, 23, 35].

The infestation rate of *H. molitrix* with *L. cyprinacea* was about 64%, this result were agree with Barson *et al*. (2008) [9] who reported that the greatest peak season for the parasite occurred in October to December (hot and wet season) also nearly similar with the results obtained by Raissy *et al*. (2013) [32] who recorded that the total infestation of different carp species was 69.4% and the highest seasonal prevalence of *Lernaea cyprinacea* was recorded in spring, summer, autumn and lowest prevalence occur in winter.

Additionally, this result was in disagreement with Iqbal *et al*. (2012) [19] who reported that the highest prevalence of the parasite in the late winter December to April (water temperature 13-23ºC) and low during the summer months, so there was appositive correlation between temperature and spreading of *L. cyprinacea*.

These results may be attributed to high temperature contribute to fast development of copepod, parasite intensity increased with mean temperatures19◦C (Barson *et al*., 2008) [9].

Since the life cycle is temperature dependent, prevalence and intensity decreases with low temperature in winter (Mancini, 2006 & Rodriguez *et al*., 2008) [24, 34] who reported that the prevalence of parasite increase with the increase in temperature with summer season, the life cycle of most species of Lernaea is completed in 100 days at 14 °C and in 7-13 days at 28 °C but the optimum temperature is between 23 °C and 30 °C.

3.2 Histopathological findings

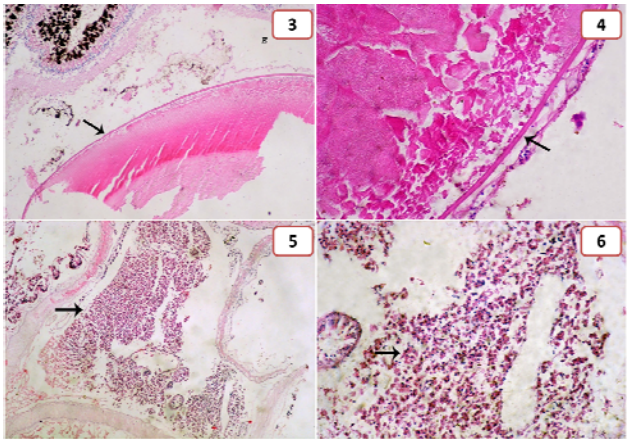

Plate 2: Histopathological findings of tissues of naturally infested Silver carp with *L. cyprinacea* showed; Lernaea with their thick wall deeply embedded in the eye with severe edema and necrosis in surrounding tissue (Photo 3), Lernaea with their thick wall embedded in the eye with mild inflammatory infiltrates around it (Photo 4) (X400, H&E); extensive edema and marked aggregations of RBCS and haemopiotic cells (Photo 5), and extensive edema, distortion in cartilaginous tissue and marked aggregations of RBCS and haemopiotic cells (Photo 6) (H&E, 100X)

The results of the histopathological alterations of *L. cyprinacea* in Silver carp were nearly agree with Joy and Jones (1973) [20] who reported that infestation was observed accompanied by an inflammatory response characterized by an extensive proliferation of fibrous connective tissue elements, wherein, both the dermis and musculature of the host were involved, distortion of cartilaginous tissues around the associated with marked aggregation of RBCs and haemopiotic cells. Due to its high pathogenicity which was achieved from highly destruction of tissues and muscles which leading to penetration, hemorrhages, and ulcerations results in blood loss, increase of monocytes, secondary infections, intense lymphocytopenia and neutrophilia (Silva-Souza *et al*., 2000 & Piasecki *et al*., 2004) [16, 29].

The most dangerous consequence of an intensive attack results in blood loss, increase of monocytes, secondary infections, intense lymphocytopenia and neutrophilia (Silva-Souza *et al*., 2000) [36]. The adults of *L. cyprinacea* leave large holes with round openings in the muscle and skin allow the entrance of secondary microbial infections causing death of the fish (Amina El-Mansy, 2009) [3].

3.3 Results of physico-chemical properties of water at Manzala area

Table 1: The water quality parameters of 6 private farms during autumn 2015.

locality	DOmg/l	pH	Salinity g/l	Po4mg/l	No3 ppm	N02 ppm	Ammonia ppm	NH3 ppm	SO4 ppm	CU3+ ppm	Fe (Fe2+,Fe3+)	H2S+ Mg/l	Temp C°
Hadous	3	7	1	2	1.4	0.2	0.02	0.0001	traces	0.03	0.16	0.01	22
Private farms	7	7.5	1	2.21	1.7	0.2	0.15	0.002	traces	0.00	0.00	0.02	18

Table 2: The water quality parameters (Alkalinity, Hardness and Transparency) of 6 private farms.

Parameter	Alkalinity ppm	Hardness ppm	Turbidity
Hadous	85	92	23
Privet farm	115	180	23

The results of water quality parameters were shown in Table 1 & 2 revealed elevation of the levels of Nitrite (0.2ppm) in private fish farm and Hadous drainage, total ammonia (0.15ppm), level of H_2S (0.2 ppm), dissolved oxygen (7 mg/L) and with alkaline pH, but the other parameters were within the permissible limits, also there are beginning of decreasing of water temperature about 16°C – 18 °C in autumn season.

The risk of parasite pathogenicity depends on the affected organ, parasitism intensity, environmental conditions and concomitant infections, among other factors (Plaul *et al*., 2010) [30].

The dissolved oxygen level is about 7mg/l which is suitable for the proliferation of *L. cyprinacea* also host densities in the pond is very high (about 3 million fry / 2 Fedan) which encourage the appearance of outbreak this result agree with the (Barson *et al*., 2008) [9].

3.4 Results of the field trial treatment of Lernaea

Our results concluded that the infestation rate of Lerneosis was elevated with poor water quality and Trichlorfon can effectively eradicate *L. cyprinicae* from the infested fish. These results were agreed with Kashara (1962) [21].

The results were not in concordance with several reports; several authors demonstrate several chemical for the control of *L. cyprinicae* as Formalin (Putz and Bowen, 1964) [31], Lexone (Gopalkrishan, 1964) [14], Benzene hexachloride (Hoffman and Mayer, 1974) [18], and Potassium permanganate as dipping at 0.0 25 mg/l for 30 seconds in Lerneosis (Gratzek, 1988; Amer and Saleh, 1990; Noga, 1996; Zaki, 1999 and Abd El-Moula, 2001) [15, 35, 28, 39, 1].

4. References

1. Abd El- Moula IH. Studies on the control of prevailing parasitic diseases among ornamental fish. MVSc. Thesis, Faculty of Veterinary Medicine, Suez Canal University. 2001.
2. Amer OH, Saleh G. Some preliminary studies on the major communicable ectoparasitic protozoa in Abassah farm Sharkia province and their treatment. Zag Vet J. 1990; 18(5):29-40.
3. Amina I El-Mansy. On the occurrence of adult females of Lernaea species (Crustacea: Copepoda) parasitic on goldfish Carassius auratus (Linnaeus) in some commercial aquaria in Egypt. Egypt J Aquat Biol & Fish. 2009; 13(1):7-36.
4. Amlacher E. Textbook of fish disease". T.F.H. Publications, New Jercy. 1970, 117-135.
5. APHA. Standard Methods for Water and Wastewater Examination and Tests. New York, USA: APHA, American Public Health Association. 1992.
6. Austin B, Austin DA. Bacterial fish pathogens: Diseases in farmed and wild fish. Ellis Harwood Limited England, 1987, 250-262.
7. Awad SM. Studies on some prevailing parasitic diseases among cultured carp fishes. M.V.Sc., Fish Diseases and Management Dept., Fac. Of Veterinary Medicine, Suez Canal University. 2007.
8. Barson M, Marshall BE. The occurrence of the tapeworm, *Ligula intestinalis* (L.), in Barbus paludinosus from a small dam in Zimbabwe. Afri J Aquat Sci. 2003; 28:75-78.
9. Barson M, Mulonga A, Nhiwatiwa T. Investigation of a parasitic outbreak of Lernaea cyprinacea Linnaeus (Crustacea: Copepoda) in fish from Zimbabwe. Afri. J. Zoo. 2008; 43:175-183.
10. Carleton MA, Dury RA, Wallington EA, Cameron H. Carleton̊ s Histopathological technique 4th edition. Oxford University. Press, New York, Toronto. 1967.
11. Carnevia D, Speranza G. First report of Lernaea cyprinacea L., 1758 in Uruguay, introduced by goldfish Carassius auratus (L., 1758) and affecting axolotl Ambystoma mexicanum (Shaw, 1758). Bulletin of the European Association of Fish Pathologists, 2003; 23(5):255-256.
12. Coche AG, James FM, Thomas L. Management for freshwater fish culture, fish stocks, and farm management. Paperback, 370 Pages, by Food & Agriculture Organization of the United Nations (FAO), ISBN-13: 978-92-5-102995-4, ISBN: 92-5-102995-4. 1998.
13. Eissa IAM. Parasitic fish diseases in Egypt. Dar El-Nahda El – Arabia Publishing 32 Abd El- Khalek Tharwat st. Cairo, Egypt. 2002.
14. Gopalkrishan V. Recent development in the prevention and control of parasites of fishes cultured in Indian water. Proc. Zool. Soc. India, 1964; 17:85-100.
15. Gratzek JB. Parasites associated with ornamental fish. Vet. Clinics of North America: small animal practice. 1988; 18(2).
16. Hanna MI. Epizootiological studies on parasitic infections in fishes cultured under different fish cultural systems in Egypt. Thesis for Ph.D. Fish Diseases and Management Cairo University Fac. of Vet. Med. 2001.
17. Hoffman GL. Parasites of North American freshwater fishes, second ed, Cornell University Press, Ithaca, NY. 1999.
18. Hoffman GL, Meyer FP. Parasites of fresh water fishes. THF. N.J. 1974, 244.
19. Iqbal Z, Shafqat A, Haroon F. Lernaea diversity and infection in Indian and Chinese carps under Semi-intensive culture conditions in Lahore, Punjab. J Anim Pl Sci. 2012; 22:923-926.
20. Joy JE, Jones LP. Observations on the inflammatory

response within the dermis of a white bass, Morone chrysops (Rafinesque), infected with Lernaea cruciata (Copepoda: Caligidea). J Fish Biol. 1973; 5:21-23.
21. Kashara S. Studies on biology of parasite copepod Lernaea cyprinacea L. and methods for controlling this parasite in the fish culture ponds (in Japanese English summary). Contr. Fish Lab. Fac. Agric. Univ. Tokyo, 1962; 3:103-196.
22. Kugel B, Hoffman RW, Fries A. Effect of low pH on the chorion of rainbow trout and Brown trout. J of Fish Biology, 1990; 37:301-310.
23. Lazar M. Morphological basis of sweet water fish diseases from fish farms. Ph.D., Normal and Pathological Morphology dept., Fac. Of Veterinary Med., Univ. Of Agricol. Science and Veter. Med. 2009.
24. Mancini M. Main diseases of pejerrey (Odontesthes bonariensis) in central Argentina. Pesquisa Veterinária Brasileira. 2006; 26(4):205-210.
25. McAllister CT, Bursey CR, Martin SD. Lernaea cyprinacea (Crustacea: Copepoda: Lernaeidae) Hydropsychidae) in Northeastern Oklahoma, Proc. Okla. Acad. Sci. 2011; 91:37-40.
26. Mediros ESF, Maltchik ADL. The effects of hydrological disturbance on the intensity of infestation of Lernaea cyprinacea in an intermittent stream fish community. J Arid Environ. 1999; 43:351-356.
27. Nagasawa K, Inoue A, Myat S, Umino T. New Host Records for Lernaea cyprinacea (Copepoda), a Parasite of Freshwater Fishes, with a Checklist of the Lernaeidae in Japan (1915 – 2007). Journal Graduate School of Biosphere Science, 2007; 46:21-33.
28. Noga EJ. Fish diseases, diagnosis and treatment. Copy right Mosbyyear book, Inc. St. Louis, Missouri. 1996.
29. Piasecki W, Goodwin AE, Eiras JC, Nowak BF. Importance of Copepoda in freshwater aquaculture. Zool. Stud. 2004; 43:193-205.
30. Plaul SE, García N, Barbeito CG. Distribution of the exotic parasite, Lernaea cyprinacea (Copepoda, Lernaeidae) in Argentina. Bull. Eur. Ass. Fish Pathol., 2010; 30(2):65-67.
31. Putz RE, Bowen JT. Parasites of freshwater fishes IV miscellaneous. The anchor worm (Lernaea cyprinacea) and related species. U.S. Bureau of Sports, Fisheries and Wildlife, Fisheries Leaflet. 1964; 575:4.
32. Raissy M, Sohrabi HR, Rashedi M, Ansari M. Investigation of a parasitic outbreak of Lernaea cyprinacea. 2013.
33. Refaat M. Immunological studies on the causative agent of columnaris disease of freshwater fish. Ph. D. Thesis submitted to Fac. Vet. Med. of Suez Canal University. 2000.
34. Rodríguez I, Beatriz N, Antonio F. Immune response of zebrafish (Danio rerio) against a newly isolated bacterial pathogen Aeromonas hydrophila. Fish & shellfish immunology, 2008; 25(3):239-249.
35. Saleh OA, Abel-Wahab AM, El-Ashram AMM. Studies on Lerneosis among cultured common carp (Cyprinus carpio) with special reference to its prevention by vaccination. Abbassa Int J Aqua. 2010; 3(1):260-276.
36. Silva-Souza A, Almeida T, Machado S. Effect of the infestation by Lernaea cyprinacea Linnaeus, 1758 (Copepoda, Lernaeidae) on the leucocites of Schizodon intermedius Garavello and Britski, 1990 (Osteichthyes, Anostomidae). Revista Brasileira de Biología, 2000; 60(2):217-220.
37. Silva-Souza A, Almeida T, Machado S. Effect of the infestation by Lernaea cyprinacea Linnaeus, 1758 (Copepoda, Lernaeidae) on the leucocites of Schizodon intermedius Garavello and Britski, 1990 (Osteichthyes, Anostomidae). Revista Brasileira de Biología. 2003; 60(2):217-220.
38. Yashouv A. On the biology of Lernaea in fish ponds. Bamidgeh, 1959; 11:80-89.
39. Zaki VH. A trials for treatment of some skin parasites causing mass mortalities among *Oreochromis niloticus* in Manzala hatchery. Beni-Suef Vet Med J. 1999; 3(3):287-297.