ISSN: 2347-5129
IJFAS 2014; 2(1): 65-71

www.fisheriesjournal.com
Received: 16-07-2014
Accepted: 01-08-2014

Ali Gül
Gazi University, Gazi Education Faculty Department of Biology Education 06500 / Teknikokullar / Ankara/Türkiye

Nurcan Uzel
Gazi University, Gazi Education Faculty Department of Biology Education 06500 / Teknikokullar / Ankara/Türkiye

Ayhan Özkul
Ankara University, Faculty of Veterinary Sciences, Department of Pathology Ankara / Türkiye

Belda Erkmen
Aksaray University, Faculty of Science, Deparment of Biology Aksaray/Türkiye

Sezin Düzel
Gazi University, Gazi Education Faculty Department of Biology Education 06500 / Teknikokullar / Ankara/Türkiye

Göktuğ Gül
Gazi University, Health Services Vocational School Gölbaşı/Ankara/Türkiye

Correspondence:
Ali Gül
Gazi University, Gazi Education Faculty Department of Biology Education 06500 / Teknikokullar / Ankara/Türkiye

Effects of some physicochemical properities of water on histopathological and hematological picture of fish inhabiting Emet Stream

Ali Gül, Nurcan Uzel, Ayhan Özkul, Belda Erkmen, Sezin Düzel, Göktuğ Gül

Abstract
This study deals with the physicochemical water parameters of Emet Stream and their histopathologic and hematologic effects upon *Squalius cephalus, Capoeta tinca, Barbus plebejus* and *Alburnoides bipunctatus* living there. The changes of the fish tissues were determined by the use of routine histological methods. The hematocrit levels of the bloods taken from the fish were also estimated. NO_2, PO_4^{3-}, Ni, as and B values were observed to be above the stipulated levels. There were bronchitis, telangiectasia, epithelial lifting and passive hyperemia determined in gills; focal hepatitis, vena centralis, hydropic and vacuolar degeneration were seen in livers; there were hemorrhages in kidney tissue and enteritis was encountered. Bronchitis and telangiectasis were intensively observed in *S. cephalus* and *C. tinca* specimens. Focal hepatitis was much more intensive in *C. tinca*. The hematocrit levels were found to be 520.45% in *S. cephalus,* 17.55% in *A. bipunctatus*, 16.625% in *B. plebejus* and 22% in *C. tinca*. The elevated values of some water parameters of Emet Stream were actually affecting on both tissues and blood parameters of the fish.

Keywords: Emet Stream, Water parameters, Fish, Histopathology, Hematocrit.

1. Introduction

The environmental contaminants have potentially toxic effects on the aqueous ecosystems. The fish are significantly exposed to these toxic effects. The effect of the pollution on fish is determined according to mortality, leptosomatic index, hematological and blood biology as well as the pathological symptoms. The major manifestations of pollution upon the living organisms are the changes in tissues and organs [1]. Histopathologic parameters are very sensitive towards the contaminants. The most apparent symptoms of contamination are seen at the cellular level and the changes at the target organs are very important indicators of pollution. These organs may show similar or different response against the pollution [2]. Liver which shows specific histological changes with the pollution is a very good bioindicator [3]. The gills are one of the most affected organs due to the fact that they are directly exposed to the polluted media [4]. Studies carried out on gills give the most reliable results due to the fact that their structures are generally well known. The lesions in kidneys alone are not sufficient to reveal the effects of the contaminants and they must be supported by the histopathological results obtained from the other tissues [5].

The hematological parameters of the fish provide many information related the environmental factors and their physiology. The increased contamination is known to cause a very sharp decrease in the hematocrit levels of the fish [6, 7].

There are serious contamination problems regarding to some of the water quality parameters of aquatic areas located in Kütahya province especially regarding to boron and arsenic levels [8]. It was reported that there were very high heavy metal levels in the waters of Porsuk Dam Lake *Cyprinus carpio* and *Barbus plebejus* specimens living in the region [9]. It is important that the contamination level and the histopathologic and histological changes be evaluated as a whole.

This study aims mainly for determination of the water parameters regarding to the contamination of Emet Stream and their histopathological changes on various fish tissues and the hematocrit levels of the fish living in.

2. Materials and Methods

The working site of the study was the Emet Stream, an aquatic land located in Kütahya province, with a length of 90 km and average flow rate of 130 m^3/s (Fig. 1).

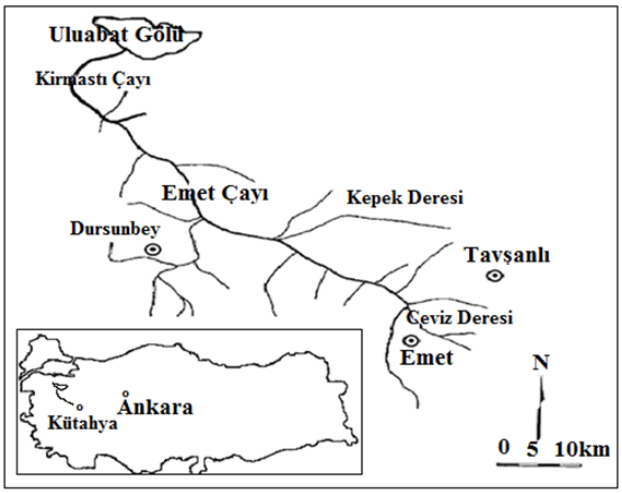

Fig 1: The map of the working site

The specimens were collected from the Hisarcık location (1st station) and the discharge point of the Eti Holding boron processing plant (2nd. station) at certain dates between 2011-2012. The temperature, pH, dissolved oxygen (DO), electrical conductivity and salinity values of the water were measured at the site using YSI brand site type oxygen meter. The NO_2, NO_3, K, Al, Mg, Zn, Cu, SO_4, Cl^-, Fe, $CaCO_3$, Ni, Ca, F^{-1}, PO_4^{3-} levels of the water samples were photometrically determined in the laboratory by the use of Palintest kits. Arsenic and boron levels of the water samples were measured spectrophotometrically with the use of ICP-MS (Agilent 7600) instrument [10]. The fish were caught by the use of trammel nets with various mesh sizes and lengths, fishing rods and throwing nets. The fish were identified by the use of Balık and Ustaoğlu [11]. The age was determined from the scales and the vertebrae of the fish. The blood samples of the fish were extracted with syringes under ice anesthesia for the biochemical and hematological investigation [12] and the fish was subjected to a necropsy for the routine histological analyses of certain tissues. The tissue samples with a thickness of 3-4 mm were fixed 10% neutral formal solution, treated with a series of alcohol, xylol and paraffin and blocked in paraffin. The cross section of 4-5 microns from these blocks was stained with Hematoxylin-Eosin (HE) [4]. The microscope pictures were taken and transferred in to the digital medium. The hematocrit levels in the blood were determined by the use of microhematocrit method. The samples taken from each fish by syringes transferred into hematocrit pipettes and placed into the microhematocrit centrifuge after their tips had been tightly sealed. The hematocrit concentrations were measured after a four minute centrifugation at 11.5 rpm [13].

3. Results and discussion

3.1. Fish

Table 1 lists the types and some biological features of the fish belonging to Cyprinidae family living in Emet Stream. Of course this aquatic land contains more than the fish species listed here. However this study was limited to the fishing periods. The most predominant species caught was *C. tinca* (30.9%) followed by a *S. cephalus* with 29.4%, *B. plebejus* with 26.4% and *A. bipunctatus* with 13.2%. Among these species *S. cephalus, C. tinca* and *B. plebejus* are widely distributed in Turkish internal aquatic lands [11].

Table 1: Some of the biological features of the fish species living in Emet Stream

Fish species	N	Age range	Fork length (Min-Max)	W (Min-Max)
Squalius cephalus (L.,1758)	20	0-IV	12.86 (8.2-24.0)	34.67 (7.92-201.5)
Capoeta tinca (H.,1843)	21	0-IV	13.83 (10-20)	44.40 (15.5-144.7)
Barbus plebejus (B.,1832)	18	0-V	16.92 (12.8-22.5)	58.97 (26.78-141.34)
Alburnoides bipunctatus (B.,1782)	9	0-IV+	9.92 (9.5-11)	13.73 (11.31-19.3)

3.2. Water

The physicochemical features of the water are listed in Table (2); where as the fresh waters are classified as follows according to the quality standards: Class 1: High quality water, Class II: Low contamination, Class III: High contamination and Class IV: Extreme contamination [14].

It is clear from the table that the nitrite, nickel, phosphate, arsenic and boron levels are above the nationally and internationally stipulated standards. The values of the other water quality parameters are not at the levels which may pose a serious threat to Emet Stream. The physicochemical parameters in the fresh waters effect the distribution, feeding habits, breeding season, physiological features and fecundity of the fish living there [18, 19]. Emet Stream can be classified as Class II aquatic land with low contamination.

The increase of nitrite above 1 mg/L is regarded as a serious signal for the initiation of contamination in fresh waters [20]. The nitrite level of Emet Stream was found to be 0.30 mg/L which poses no threat for the region. Nickel is introduced to the aqua lands by industrial effluents. The exposure of nickel above the acceptable levels causes serious physiological and histological complications [21]. That is why its levels should be closely monitored. The nickel level in this study was found to be 0.19 mg/L which shows that Emet Stream can be regarded Class III highly contaminated land regarding to nickel levels.

Phosphate (PO_4^{3-}), which is an important indicator of the contamination of the aquatic lands, is introduced to the wet lands due to dissociation of organic matter, domestic effluents, chemical fertilizers and chemicals agents. Its excessive presence in water changes the pH value of water which has an important effect upon the organisms living there. It is reported that the phosphate content of 0.15 mg/L is the sign of high productivity while the values above 0.30 mg/L is the indication of presence of high level contamination [20]. The average phosphate level of Emet Stream was found to be 29.05 mg/L which is the indication of the heavy contamination regarding to phosphate level. Arsenic is known to be one of the most toxic metals on the living organisms. It is reported that it is densely present in soil, drinking water and streams much above the levels stipulated by the national and international standards [8]. The

average arsenic level determined in this study was 38.23 mg/L which was the indication of class IV extreme arsenic contamination.

Table 2: Emet Stream water quality parameters

Parameters	25.06.2011		21.07.2011		21.06.2012		20.10.2012		TSE 266, [15].	WHO, [16].	USEPA, [17].	YSKYY, [14]. (Class 2.)
	1. Sta.	2. Sta.	1. Sta.	2. Sta.	1. Sta.	2. Sta.	1. Sta.	2. Sta.				
Temperature (°C)	25.3	22.4	25.0	23.7	18.8	23.5	14.8	17.2	-	-	-	25
pH	9.29	9.01	8.48	8.68	8.85	8.98	7.89	7.66	6.5-9.5	-	-	6.5-8.5
Dissolved oxygen (mg/L)	9.45	9.50	7.83	5.89	7.82	9.71	9.35	8.64	-	-	-	6
Conductivity (µS/cm)	319.1	828.0	856.0	995.0	759.0	833.0	721.0	807.0	2500	-	-	-
Salinity (ppt)	0.15	0.43	0.42	0.05	0.42	0.48	0.44	0.47	-	-	-	-
Nitrite (NO_2) (mg/L)	0.26	0.87	0.08	0.95	0.053	0.105	0.043	0.053	0.50	-	-	0.01
Nitrate (NO_3) (mg/L)	3.70	>>	2.04	>>	2.90	2.70	0.76	0.74	50	-	-	10
Potassium (K) (mg/L)	5.5	6.4	3.8	7.8	3.5	5.4	3.4	3.6	-	-	-	-
Aluminum (Al) (mg/L)	<<	<<	<<	<<	<<	<<	<<	<<	0.20	0.20	0.20	0.3
Magnesium (Mg) (mg/L)	50	42	39	42	70	75	43	45	-	-		
Zinc (Zn) (mg/L)	0.03	0.01	0.02	<<	0.00	0.00	0.02	0.00	-	5	5	0.50
Copper (Cu) (mg/L)	0.02	0.00	0.02	0.01	0.08	0.02	0.00	0.00	2	2	1.3	0.05
Sulfate (SO_4) (mg/L)	195	195	195	195	195	195	195	190	250	-	-	-
Chloride (Cl^-)(mg/L)	13	6	6	8	2	12	4	8	250	250	250	200
Iron (Fe) (mg/L)	0.02	0.01	0.00	0.01	0.01	0.03	0.00	<<	0.2	0.3	0.3	1
Alkalinity ($CaCO_3$) (mg/L)	210	210	235	210	235	165	240	230	-	500	-	-
Nickel (Ni) (mg/L)	0.05	0.05	0.10	0.05	0.30	0.15	0.60	0.25	0.02	0.02		0.05
Calcium (Ca) (mg/L)	90	85	110	88	71	66	94	97	-	300	-	-
Fluoride (F^{-1}) (mg/L)	>>	0.02	1.15	0.02	1.24	>>	1.11	1.13	1.5	1.5	2	1.5
Phosphate (PO_4) (mg/L)	25.1	25.5	13.6	22.6	15.4	34.7	46.4	49.1				
Arsenic (As) (mg/L)	-	85.00	-	2.421	4.697	107.9	14.49	14.90	0.01	0.01	0.01	0.05
Boron (B) (mg/L)	-	5.562	-	0.137	0.342	7.911	1.002	0.924	-	-	-	1

Boron compounds are also extensively present in the ground and underground waters ranging from 0.01 to 1.5 mg/L [22]. Boron was reported to be densely present in the site investigated in this study [8]. The 2.65 mg/L average level of boron determined in this study was above the water quality standards and constitutes a serious threat against the fish living in Emet Stream. It is apparent that Emet Stream is highly contaminated as regards to arsenic and boron coming from the industrial sites and settlements located around the site which may cause histological and hematological complications.

3.3. Histopathological findings

The cross sections taken from the fish tissues were subjected to histopathological analyses (Table 3). There were bronchitis and hyperemia observed in the gills of *S. cephalus, C. tinca, B. plebejus and A. bipunctatus* species (Fig. 2). Also there was telangiectasis at the gills of *S. cephalus* (Fig. 3). There was epithelial lifting in some of the *A. bipunctatus* specimens (Fig. 4). The liver tissues of *S. cephalus, C. tinca* and *B. plebejus* were observed to be degenerated. The livers of *C. tinca, B. plebejus* and *A. bipunctatus* specimens were seen to have focal hepatitis and vena centralis and the sinusoids *C. tinca* and *B. plebejus* samples were full of erythrocytes (passive hyperemia) (Fig. 5). In liver histopathology of some specimens there were mono nuclear cell infiltrations located as focal areas dominated by lymphocytes. In some liver samples there were occasional hydroscopic and vacuolar degeneration observed. The histopathological renal investigation of some *B. plebejus* revealed hemorrhages (Fig. 6). Also enteritis was determined in the digestion track of some of the *C. tinca* and *A. bipunctatus* specimens. Bronchitis and telangiectasis were observed to be dominant in *S. cephalus* and *C. tinca* samples. The focal hepatitis, determined in the livers of some fish, was found to be much more dominant in *C. tinca* samples (Fig. 7). There were no histopathological investigations made on gonads, muscles and brain tissues.

Table 3: Histopathological findings of the tissues of the fish living in Emet Stream

Tissue	Pathological findings	*S. cephalus*		*C. tinca*		*B. plebejus*		*A. bipunctatus*	
		1st sta.	2nd sta.	1st sta.	1st sta.	1st sta.	1st sta.	1st sta.	1st sta.
Gills	Bronchitis	+	+	+	++	+	-	-	-
	Telangiectasis	+	++	++	++	-	-	-	-
	Epithelial lifting	-	-	-	-	-	-	-	+
	Hyperemia	+	+	+	++	+	++	+	++
Livers	Degeneration	+	+	+	+	+	-	-	-
	Focal Hepatitis	-	-	-	++	+	-	-	-
	Passive Hyperemia	-	-	+	-	+	-	-	-
Kidneys	Hemorrhage	-	-	-	-	+	-	-	-
Digestion track	Enteritis	-	-	+	-	-	-	+	-

(-): No histopathological finding; (+): Histopathology < 20%; (++): Histopathology is between 20-60%

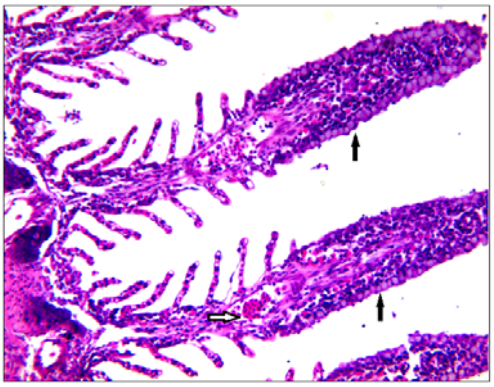

Fig 2: Hyperemia (⇨) and Bronchitis (➡) in the gill lamellae of *C. tinca* (HE, x 10)

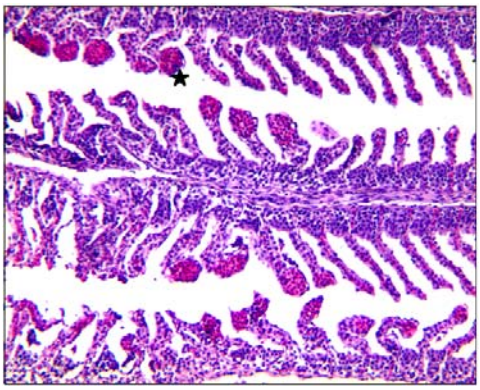

Fig 3: Telangiectasis (★) in the gill lamellae of *S. cephalus* (HE, x 20)

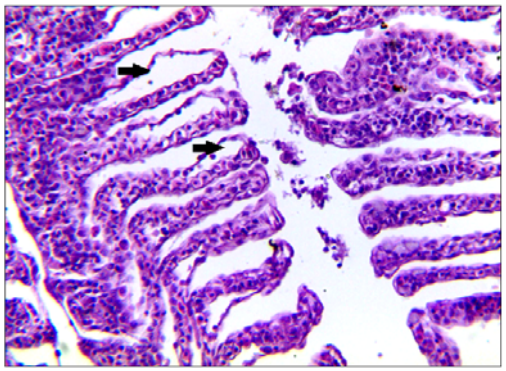

Fig 4: Epithelial Lifting (➡) in the gill lamellae of *A. bipunctatus* (HE, x 20)

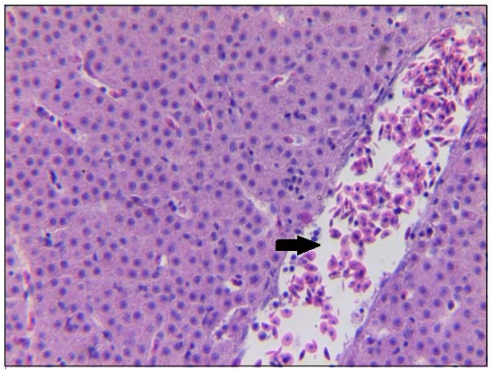

Fig 5: Passive Hyperemia (➡) in the liver of *B. plebejus* (HE, x 20)

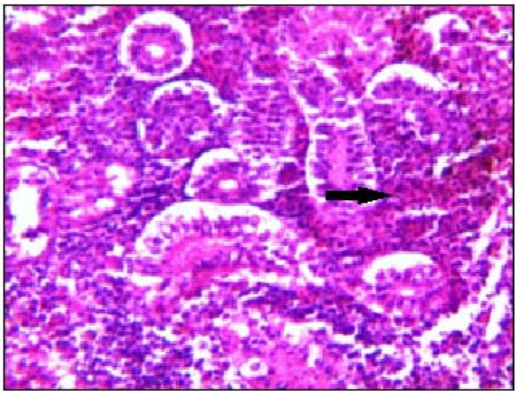

Fig 6: Degeneration and hemorrhage (➡) in the kidneys of *B. plebejus* (HE, x 20)

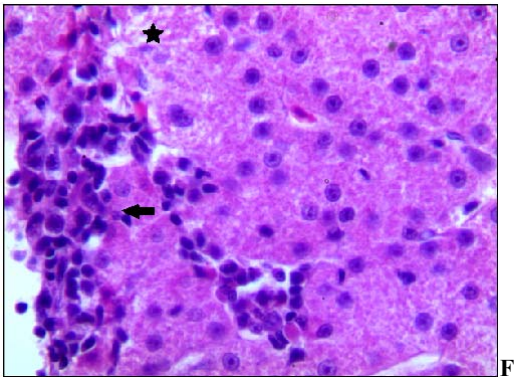

Fig 7: Focal Hepatitis (★) and Degeneration (➡) in the liver of *C. tinca* (HE, x 20)

The investigations of the harmful effect of environmental factors on the aquatic organisms and the resulting structural and functional changes in histopathological point of view have become very popular in recent years. It is known that the environmental factors have always a histopathological potential upon the aquatic media [23, 1].

The mostly affected organ of the fish by the contaminants is the gills. The gills of the fish which were directly exposed to the contaminants were observed to develop bronchitis, telangiectasis, epithelial lifting, hyperemia, enlargement of the capillaries and necrosis [4, 24 and 25]. The fact that some chemicals such as heavy metals result a very heavy damage on the gills of the fish exposed to the contaminated media is in good compliance with the findings of the current study [26, 27, 28, 29, 30 and 31]. There are important histological changes take place in the livers of the fish exposed to the toxic compounds [32]. It is the most susceptible organ to the toxic effect where the complications such as degeneration, hyperemia, fattening, clogging in capillaries and sinusoids, necrosis and changes in the hepatozoid structure are observed [33, 34]. The kidneys are as seriously affected as livers and gills by the toxic compounds. However the lesions in kidneys are not enough to verify the contamination. It must be supported by other histopathological data of the other organs. The histopathological findings frequently observed in kidneys are necrosis, fibrin and hemorrhage [35, 1]. The histopathologic complications observed in the digestive track are the hydropic degeneration of digestion gland, proliferation of the mucus cells and lesions [35]. There was also enteris observed in the digestive tracks of *C. tinca* and *A. bipunctatus* in this study.

The literature data upon the effects of the environmental factors on the various tissues are in good accordance of the data obtained in *S. cephalus, C. tinca, B. plebejus* and *A. bipunctatus* living in Emet Stream. There is a serious indication that Emet Stream is being rapidly contaminated as regards to some parameters and these factors cause significant changes in the gills and liver tissues of the fish species living there. The the most exposed organ to the contaminants in the aqueous media are the gills. This is manifested by a significant increase in mucus secretion as a reaction to this exposure. This decreases the oxygen diffusion through the respiratory surfaces. The hyperplasia observed especially in the supporting cells and the cells rich in mitochondria also proves that the gills are the most effected organs by the external factors. However the effects of these factors upon kidneys and digestion tract are much less than their effects on livers and gills.

3.4. Hematocrit value

The hematocrit levels of the blood are the most important indication of the health of fish (Table 4). The hematocrit levels are dependent upon the height, weight, gender composition and seasonal variations and change according to the species of the fish [36]. The hematocrit levels found for different fish species at different water systems are as follows: At the study they carried out by Haşiloğlu and Atamanalp [37] on *Leuciscus cephalus* living in Demirdöven Dam Lake (Erzurum) reported the hematocrit levels as 37 ± 5.4%. Atamanalp *et al*, [6] reported that these levels were 46.22±4.55% in the first and 44.00±5.29% in the second station for *Capoeta capoeta capoeta* living in Tuzla stream. The other results obtained for different species were 12-35% for *Acanthobrama marmid,* living in Keban Dam Lake [38], 30.5±2.2% for *Cyprinus carpio,* 28.9±1.8% for *Leuciscus cephalus*, 27.6±1.4% for *Capoeta trutta* and 31.4±1% for *Capoeta capoeta umbla* in Sultansuyu (Malatya) [39]. The literature data show that the hematocrit levels show great variation according to the species investigated. The increase in the contamination parameters also cause the hematocrit levels to decrease. It is reported that the hematocrit levels of *Cyprinus carpio*' decreased from 27.4 to 24.9 ± 1.9% in contaminated media [40]. The changes of hematological parameters of fish, which constitute an important protein source for humans, give important clues about the environmental factors and their physiologic development [7]. The hematocrit levels of the fish living Emet Stream show parallelism with some of the results reported in literature. However the results are different compared with the majority of the data reported. This may be due to the adverse effects of the contaminants.

Table 4: Hematocrit levels of the fish living in Emet Stream

Species	N	Hematocrit (%) ± S (Min-Max)
S. cephalus	5	20.45±2.81 (17.3-25.6)
C. tinca	5	22.04±4.61 (16.4-27)
B. plebejus	5	16.63±6.08 (9-25)
A. bipunctatus	5	17.55±2.09 (15-20.5)

4. Conclusion

YSKYY [14] criteria indicate that Emet stream is a 2nd. class low polluted aqueous region according to water paremeters. The nitrite, nickel, phosphate, arsenic and boron levels were found to be above the nationaly [14, 15] and internatoinally [16, 17] accepted standarts. Among these parameters the level of boron (with a mean value of 2.65 mg /L) constitutes an important thread to the environment as regards to water quality standarts. The arsenic and boron pollution was thought to be the result of the industrial plants located within the close vicinity of the stream. The histopathological complications and hematological changes observed in fish were attributed to these pollutants. Therefore it was concluded that the fish caught from Emet stream should not be consumed by the local people.

5. Acknowledgement

This study was supported by the Gazi Universty Scientific Research fund (BAP, 04/2011-15).

6. References

1. Uçar A, Atamanalp M. Toxicopathological lesions in fish I. Journal of the Faculty of Agriculture Atatürk University 2008; 39(2):255-261.
2. Stentiford GD, Evans M, Bateman K, Feist SW. Co-infection by a yeast-like organism in hematodinium-infected European edible crabs cancer pagurus and velvet swimming crabs necora puber from the english channel. Diseases of Aquatic Organisms 2003; 54(3):195-202.
3. Abdel-Moneim AM, Al-Kahtani, MA, Elmenshawy, OM. Histopathological biomarkers in gills and liver of *Oreochromis niloticus* from polluted wetland environments Saudi Arabia. Chemosphere 2012; 88(8):1028-1035.
4. Mallat J, Fish gill structural changes induced by toxicants and other irritants: A statistical rewiew. Can J Fish Aquat Sci 1985; 42(4):630-648.
5. Mishra AK, Mohanty B. Histopathological effects of hexavalent chromium in the ovary of a fresh water fish *Channa punctatus* (Bloch). Bull Environ Contam Toxicol 2008; 80 (6):507-511.
6. Atamanalp M, Kocaman EM, Canyurt MA. The effect of domestic effluents upon the hematocrit and sediments levels of *Capoeta capoeta capoeta* (Güldenstaedt, 1772).

Ege University Journal of Fisheries & Aquatic Sciences 2002; 19(3-4):439-445.
7. Uçar A, Atamanalp M. Toxicopathological lesions in fish II. Journal of the Faculty of Agriculture Atatürk University 2009; 40(1):95-101.
8. Ünlü Mİ, Bilen M, Gürü M. Investigation of boron and arsenic pollution in Kütahya–Emet region underground water samples. J Fac Eng Arch Gazi University 2011; 26(4):753-760.
9. Çiçek A, Koparal AS. The levels of lead, chromium and cadmium in the *Cyprinus Carpio* and *Barbus Plebejus*, living in Porsuk Reservoir. Journal of Environmental Protection 2001; 10(39):3-6.
10. USEPA Method 200.7. Revision 5.0. Trace elements in water, solids, and biosolids by inductively coupled plasma-atomic emission spectrometry. EPA-821-R-01-010, 2001.
11. Balık S, Ustaoğlu MR. The handbook of internal water fish of Turkey. Ege University Faculy of Fisheries Publications 63. Guide Book Series 10. Ege University Publishing House, İzmir, 2004.
12. Franco JL, Trevisan R, Posser T, Trivella DBB, Hoppe R, Rosa JM *et al*. Biochemical alterations in caged nile tilapia *Oreochromis niloticus*. Ecotox Environ Saf 2010; 73(5):864-72.
13. Blaxhall PC, Daisley KW. Routine haematological methods for use with fish blood. J Fish Biol 1973; 5:771-781.
14. YSKYY. Surface Water Quality Management Regulation. 30 November 2012 date and 28483 numbered TR Official Gazette (Annex-5), 2012.
15. TSE 266. Water and water intended for human consumption. Turkish Standards Institution 2005.
16. WHO. Guidelines for drinking-water quality, second edition, volume: 2 health criteria and other supporting information, Geneva, 1996.
17. USEPA. National recommended water quality criteria. EPA-822-R-02-047, 2002.
18. Suski CD, Killen SS, Keiffer JD, Tufts BL. The influence of environmental temperature and oxygen concentration on the recovery of large mouth bass from exercise: implications for live-release angling tournaments. J Fish Biol 2006; 68(1):120-136.
19. Lawson EO. Physico-chemical parameters and heavy metal contents of water from the mangrove swamps of lagos lagoon, lagos, Nigeria. Advances in Biological Research 2011; 5(1):08-21.
20. Nisbet M, Verneaux J. Composantes chimiques des eaux courantes, discussion et proposition de classes en tant que bases d'interprepretation des analyses chimiques. Annales de Limnologie 1970; 6(2):161-170.
21. Borba CE, Guirardello R, Silva EA, Veit MT, Tavares CRG. Removal of nickel (II) ions from aqueous solution by biosorption in a fixed bed column: experimental and theoretical breakthrough curves. Biochemical Engineering Journal 2006; 30(2):184-191.
22. Kabay N, Yılmaz I, Bryjak M, Yüksel M. Removal of boron from aqueous solutions by ion exchange-membrane hybrid process. Desalination 2006; 198(1-3):74-81.
23. Schwaigera J, Ferlinga H, Mallowa U, Wintermayrb H, Negelea RD. Toxic effects of the non-steroidal anti-inflammatory drug diclofenac Part I: histopathological alterations and bioaccumulation in rainbow trout. Aquatic Toxicology 2004; 68(2):141-150.
24. Koca YB, Koca S, Yıldız Ş, Gürcü B, Osanç E, Tunçbaş O *et al*. Investigation of histopathological and cytogenetic effects on *Lepomis gilbosus* (*Pisces: Perciformes*) in the Çine Stream (Aydın/Turkey) with determination of water pollution. Environmental Toxicology 2005; 20(6):560-571.
25. Gül A, Karasu Benli AÇ, Ayhan A, Koçak Memmi B, Selvi M, Sepici-Dinçel A *et al*. Sublethal propoxur toxicity to juvenile common carp (*Cyprinus carpio* L, 1758): Biochemical, hematological, histopathological and genotoxicity effects. Environmental Toxicology and Chemistry 2012; 31(9):2085-2092.
26. Darwish AM, Griffin BR, Straus DL, Mitchell AJ. Histological and hematological evaluation of potassium permanganate exposure in channel catfish. Journal of Aquatic Animal Health 200; 214(2):134-144.
27. Tort J, Jennings-Bashore C, Wilson D, Wooster GA, Bowser PR. Assessing the effects of increasing hydrogen peroxide dosage on rainbow trout gills utilizing a digitized scoring methodology. Journal of Aquatic Animal Health 2002; 14(2):95-103.
28. Krishnani KK, Azad IS, Kailasam M, Thirunavukkarasu AR, Gupta BP, Joseph KO *et al*. Acute toxicity of some heavy metals to lates calcarifer fry with a note on its histopathological manifestations. Journal of Environmental Science and Health Part A 2003; 38(4):645-655.
29. Olojo EAA, Olurin KB, Mbaka G, Oluwemimo AD. Histopathology of the gill and liver tissues of the African catfish *Clarias gariepinus* exposed to lead. African Journal of Biotechnology 2005; 4(1):117-122.
30. Nero V, Farwell A, Lister A, Kraak GVD, Lee LEJ, Meer TV *et al*. Gill and liver histopathological changes in yellow perch (*Perca flavescens*) and goldfish (*Carassius auratus*) exposed to oil sands process-affected water. Ecotoxicol Environ Saf 2006; 63(3):365-376.
31. Dinçel SA, Karasu BAÇ, Selvi M, Sarıkaya R, Şahin D, Özkul A *et al*. Sublethal cyfluthrin toxicity to carp (*Cyprinus carpio* L.) fingerlings: biochemical, hematological, histopathological alterations. Ecotoxicol Environ Saf 2009; 72(5):1433-1439.
32. Brusle J, Anadon GG. The Structure and function of fish liver. In: Fish Morphology, (Eds) J.S.D. Munshi & H.M. Dutta. Science Publishers Inc. CRC Pres 1996, 77-83.
33. Heath AG. Water pollution and fish physiology. CRC pres USA 1987, 96-102.
34. Mikula P, Modra H, Nemethova D, Groch L, Svobodova Z. Effects of subtronic exposure to LASSO MTX (Alachlor 42% W/V) on hematological indices and histology of the common carp *Cyprinus carpio* L. Bull Environ Contam Toxicol 2008; 81(5):475-479.
35. Lawrence AJ, Arukwe A, Moore M., Sayer M, Thain J. Molecular/cellular processes and the physiological response to pollution. In: Effects of pollution on fish: Molecular effects and population responses (Eds. Lawrence AJ, Hemingway KL) Blackwell Sciences Ltd UK, 2003, 83-133.
36. Garcia MP, Echevarria G, Martinez FJ, Zamora S. Influence of blood sample collections on the hematocrit value of two teleosts: Rainbow trout (*Oncorhynchus mykiss*) and European sea bass (*Dicentrarchus labrax* L.). Comp Biochem Physiol Part A 1992; 101(4):733-

736.
37. Haşiloğlu MA, Atamanalp M, Determinaiton of the hematological paremeters of chub (*Leuciscus cephalus*) living in Demirdöven Dam lake (Erzurum). 19 May University Journal of Agriculture 2002; 17(2):34-38.
38. Başusta GA, Şen D. Investigation into the changes in blood parameters in *Acanthobrama marmid* Heckel, 1843 living in Keban Dam Lake. Türk J Vet Anim Sci 2004; 28(1):1-6.
39. Kandemir Ş, Örün İ, Talas Z, Örün G, Erdoğan K, Işık M *et al*. Effects on mortality of biochemical and limnological properties on some fish species in Sultansuyu Dam Lake (Malatya), Turkey. Turkish Journal of Fisheries and Aquatic Sciences 2010; 10(3):431-437.
40. Kakuta I, Ishii K, Murachi S. Effects of diluted sewage on biochemical parameters of carp *Cyprinus carpio*. Comp Biochem Physiol Part C 1994; 107(2):289-294.