ISSN: 2347-5129
IJFAS 2013; 1 (1): 39-42
www.fisheriesjournal.com
Received: 23-10-2013
Accepted: 01-11-2013

V.Vidhya
PG and Research Centre, Department of Zoology, S.T. Hindu College, Nagercoil-629002, Kanyakumari District, Tamil Nadu, India.

C.Radhakrishnan Nair
PG and Research Centre, Department of Zoology, S.T. Hindu College, Nagercoil-629002, Kanyakumari District, Tamil Nadu, India

Correspondence:
V.Vidhya
PG and Research Centre, Department of Zoology, S.T. Hindu College, Nagercoil-629002, Kanyakumari District, Tamil Nadu, India.

Histopathological Changes Observed in the Gills of *Etroplus suratensis* Exposed to Pyrethroid Insecticide, Lambda-Cyhalothrin

V.Vidhya and C.Radhakrishnan Nair

ABSTRACT
Histopathological investigations on different tissues of fish are valuable tools for toxicology studies and monitoring water pollutions. Gills are the first organs which come in contact with environmental pollutants. The present attempt was made to study the histopathological changes in the gills of fish, *E. suratensis* when exposed to sub-lethal concentrations of insecticide, lambda-cyhalothrin. From the result, the most frequently observed changes when the gill come in contact with lambda-cyhalothrin on *E. suratensis* included increase in mucus, dilation of primary and secondary gill lamellae, widening of secondary gill filaments, vacuole, curved secondary lamellae, lamellar necrosis, edema, ballooning gill filament, hyperplasia. The histological changes observed in the gills of *E. suratensis* indicate that the fish were responding to the direct effects of the pesticide, lambda-cyhalothrin.

Keywords: *E. suratensis*, Gills, Histological Alterations, Lambda-Cyhalothrin

1. Introduction

Man-made toxic chemicals are released into the environment during production, transportation as well as utilization, and thus pose a threat to living biota. In the last 50 years, there has been a steady growth in the use of synthetic organic chemicals such as pesticides. Contamination of water by pesticides, either directly or indirectly, can lead to fish kills, reduced fish productivity, or elevated concentrations of undesirable chemicals in edible fish tissue which can affect the health of humans consuming these fish. Toxicants like pesticide and other chemicals find their ways into the water bodies and have produced unexpected consequences on aquatic fauna.

Histopathological investigations on different tissues of fish are valuable tools for toxicology studies and monitoring water pollutions. Histopathological biomarkers in the gills may be valuable as indicators of the general health of the fish and mirror effects of exposure to a variety of anthropogenic pollutants [17]. Gills apart from being the primary respiratory organ in fishes, are also responsible for other vital physiological functions like excretion of nitrogenous wastes, acid base balance and ion regulation. So when fish are exposed to environmental pollutants, these vital functions are deleteriously affected and the functional impairment of gills can significantly damage the health of fish [1, 8]. The gill surface is more than half of the entire body surface area. In fish the internal environment is separated from the external environment only a few microns of delicate gill epithelium and thus the branchial function is very sensitive to environmental contamination. Gills are the first organs which come in contact with environmental pollutants. Gills have frequently been used in the assessment of impact of aquatic pollutants in marine as well as freshwater habitats [2]. Therefore, lesions in gill tissues can be the start of imbalance of the physiological and metabolic process of fish. Many investigators have reported the histopathological changes in the gills of different fish species exposed to pesticides [1, 6, 12].

Histopathological techniques are rapid, sensitive, reliable and comparatively inexpensive tools for the assessment of stress-response to pollutants. Hence an attempt was made to study the histopathological changes in the gills of fish, *E. suratensis* when exposed to sub-lethal concentrations of insecticide, lambda-cyhalothrin.

2. Materials and Methods

A group of 10 fishes were exposed to 0.005 ppm, 0.006 ppm, 0.008 ppm, 0.013 ppm and 0.026 ppm (1/20, 1/16, 1/12, 1/8 and 1/4 sub-lethal concentration of LC_{50} value) for observing the histopathological changes. The treated groups and the pesticide free medium in which fishes were maintained and renewed daily. Fishes were randomly selected from control groups and treated groups, for histopathological observations by sampling after 60 days of exposure. The gills of control and pesticide treated *E. suratensis* were taken out and a histological study was carried out by employing [5] method. Selected slides were photographed by using computerized Kyowa-Trinocular Microscope with CC TV attached.

3. Results and Discussion

In the present study, the gills of *E. suratensis* in control group was shown a normal structure (Plate 1) and gills of the lambda-cyhalothrin treated groups showed several pathological changes throughout the experimental period. The changes observed in the gill of *E. suratensis* exposed to lower concentration (0.005 ppm) of lambda-cyhalothrin induced histological changes such as curved secondary lamellae and cytoplasmic vacuolation were identified (Plate 2). The fishes exposed to 0.006 ppm lead to edema, haemorrhage of gill lamellae, sloughed off cells and loosening of primary gill bar (Plate 3 and Plate 4). In *E. suratensis* exposed to 0.008 ppm, the alternations such as lamellar necrosis, edema, sloughed off cells and ballooning of secondary gill filament were also observed (Plate 5 and 6). The histological changes in 0.013 ppm included curved secondary lamellae, lamellar fusion, lamellar talengectases and edema were observed. Blood conjugation and increased mucus production were also seen on prolonged exposure to lambda-cyhalothrin (Plate 7 and Plate 8). In exposure to higher concentration (0.026 ppm), dilation of primary and secondary gill lamellae, loss of architecture and severe disorganization were identified. The primary and secondary branchial filaments suffered from edema and numbers of cuts were also observed in secondary gill lamellae. There is tendency of fusion of disorganised secondary gill filaments and tips became naked due to loss of epithelium (Plate 9 and Plate 10).

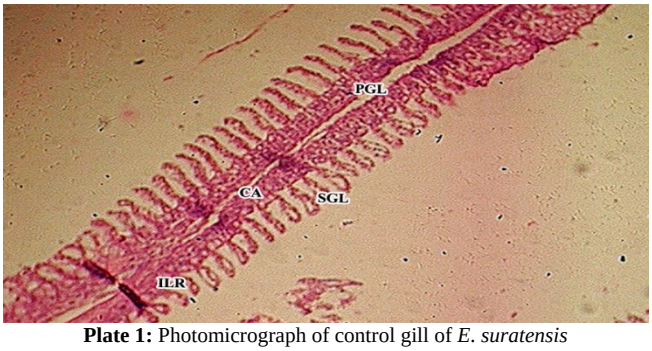

Plate 1: Photomicrograph of control gill of *E. suratensis* showing the normal gill architecture (200X)
PGL - Primary gill lamellae; SGL- Secondary gill lamellae; ILR - Inter lamellar region; CA - Central axis

After exposure of lambda-cyhalothrin, an excessive amount of mucus was observed over the gills of *E. suratensis*. It has been reported that the stress caused by the variations in the environment and pathological agents induced the proliferation of mucus cells and increased secretion [3, 13]. The large quantity of mucus secretion acts as a defense mechanism against several toxic substances [10]. The most frequently observed changes when the gill come in contact with lambda-cyhalothrin on *E. suratensis* included increase in mucus, vacuole, curved secondary lamellae, lamellar necrosis,

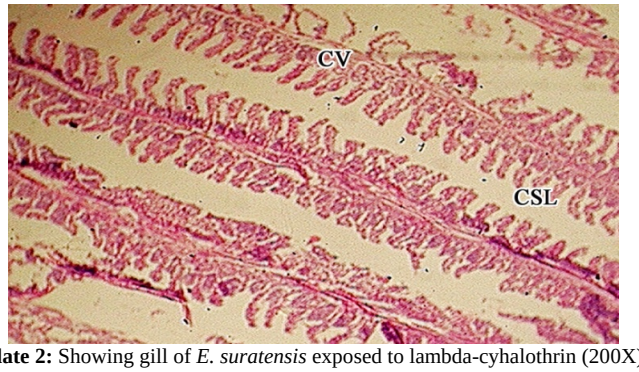

Plate 2: Showing gill of *E. suratensis* exposed to lambda-cyhalothrin (200X)
CSL- Curved secondary lamellae; CV-Cytoplasmic vacuolation

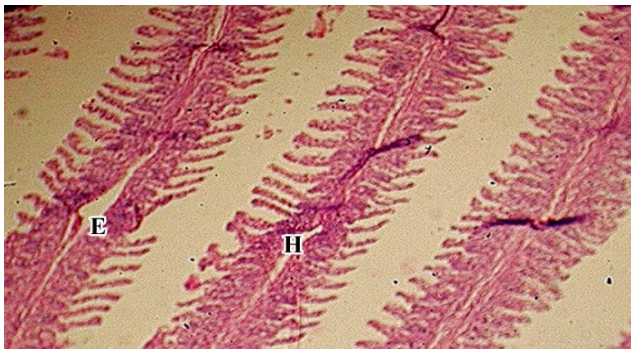

Plate 3: Showing the gill of *E. suratensis* exposed to lambda-cyhalothrin (200X)
H-Haemorhage; Ed-Edema

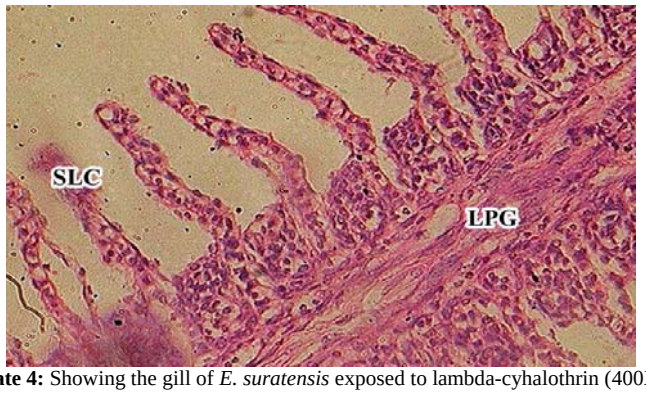

Plate 4: Showing the gill of *E. suratensis* exposed to lambda-cyhalothrin (400X)
SLC- Sloughed off cells; LPG- Loosening of primary gill bar

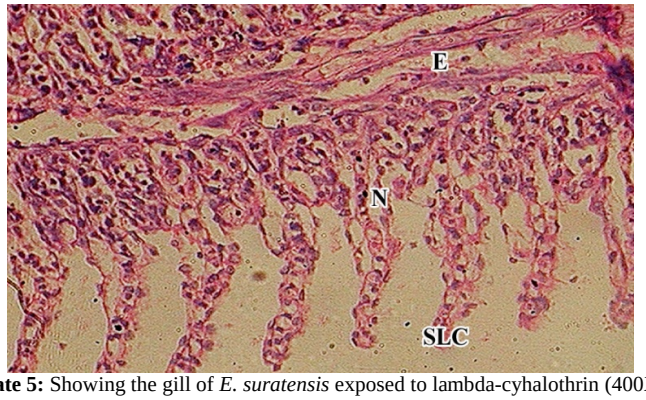

Plate 5: Showing the gill of *E. suratensis* exposed to lambda-cyhalothrin (400X**)**
LN-Lamellar necrocis; E- Edema; SLC- Sloughed off cells

edema, ballooning gill filament and haemorrhage. These findings are in reliable with the works of [12] on *C. carpio* and *O. mossambicus* exposed to different sub-lethal concentrations of karate (lambda-cyhalothrin) and curacron. The histopathological changes of gill can result in hypoxia, respiratory failure problems

Plate 6: Showing the gill of *E. suratensis* exposed to lambda-cyhalothrin (400X) E- Edema; BSG- Ballooning of secondary gill filament

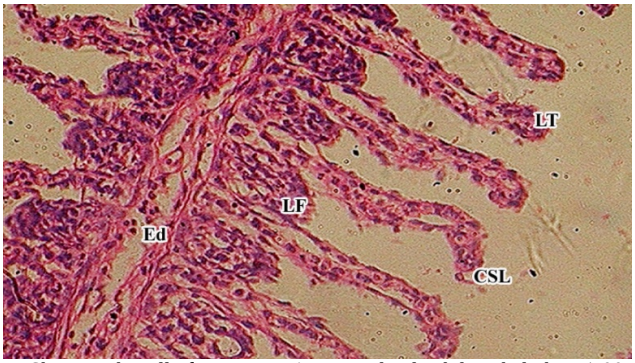

Plate 7: Showing the gill of *E. suratensis* exposed to lambda-cyhalothrin (400X) CSL- Curved secondary lamellae; LT- Lamellar talengectases; LF- Lamellar fusion; E-Edema

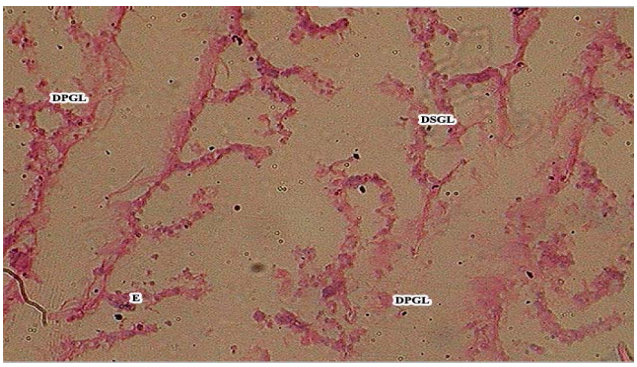

Plate 8: Showing the gill of *E. suratensis* exposed to lambda-cyhalothrin (400X) DPGL-Dilation primary gill lamellae; DSGL-Dilation secondary gill lamellae; E- Edema

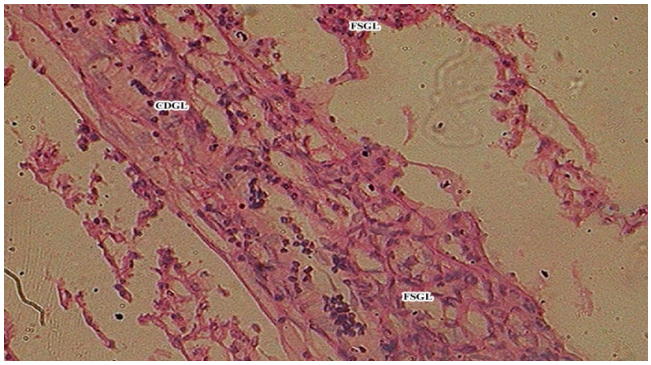

Plate 9: Showing the gill of *E. suratensis* exposed to lambda-cyhalothrin (400X) CDGL-Completely degenerated gill lamellae; FSGL-Fusion secondary gill lamellae

with ionic and acid-base balance [1]. Epithelial hyperplasia with lamellar fusion, epithelial hypertrophy, edema with epithelial separation from basement membranes and general necrosis have

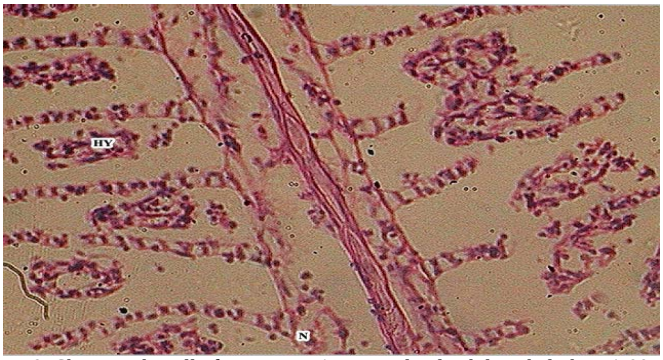

Plate 10: Showing the gill of *E. suratensis* exposed to lambda-cyhalothrin (400X) HY-Hyperplasia; N- Necrosis

reported following exposure to DDT and malathion [16] and exposure to Paraquat dichloride [7]. Similarly, Cengiz EI [4] observed histopathological effect of deltamethrin on the gill of common carp. Tilak KS [15] reported that chlorpyrifos intoxication in fish, *Catla catla* caused dropsy, vascular degeneration, cloudy swelling, necrosis and other degenerative changes in epithelial and pillar cells of the gills. Club shaped lamellae are an example of progressive degeneration in the gills. In the present study, the epithelial hyperplasia could be a consequence of the epithelial detachment [9] and lamellar fusion could be a result of both hyperplasia of epithelial cells [11]. The concentration of lambda-cyhalothrin increased, the different lamellar filaments became desquamated and completely lost their architecture indicating its failure to overcome the stress. Vacuolization and ballooning of secondary lamellae were predominant and this might be due to inflammation brought about by pesticide toxicity. Similar results were reported earlier by various authors [12]. Roy PK, Munshi JSD [14] have showed that fusion of bases of secondary gill filaments was a mechanism adopted by the fish to increase the respiratory area was affected by the pesticide toxicity. This finding was in concordance with the present study.

In conclusion, the histological changes observed in the gills of *E. suratensis* indicate that the fish were responding to the direct effects of the pesticide, lambda-cyhalothrin. Hence safety measures must be taken into account when insecticide is being used in fish inhabiting regions.

4. Reference

1. Alazemi BM, Lewis JW, Andrews EB. Gill damage in the freshwater fish *Gnathonemus petersii* (Family: Mormyridae) exposed to selected pollutants: an ultra-structural study. Environ Technol 1996; 17:225-238.
2. Athikesavan S, Vincent S, Ambrose T, Velmurugan B. Nickel induced histopathological changes in the different tissues of freshwater fish, *Hypophthalmichthys molitrix* (Valenciennes). J Environ Biol 2006; 27:391-395.
3. Cardoso EL, Chiarini-Gracia H, Ferreira RMA, Poli CR. Morphological changes in the gills of *Lophiosilurus alexandri* exposed to unionized ammonia. J Fish Biol 1996; 49:778-787.
4. Cengiz EI. Gill and kidney histopathology in the freshwater fish *Cyprinus carpio* after acute exposure to deltamethrin. Environmental Toxicology and Pharmacology 2006; 22:200–204.
5. Culling CFA. Handbook of histopathological and histochemical techniques, Edn 3, 1974.
6. Erkmen B, Caliskan M, Yerli SV. Histopathological effects of cyphenothrin on the gills of the *Lepistes reticulates*. Vet Hum Toxicol 2000; 42:71-78.
7. Hendricks JD. Effects of various herbicides on histology of yearling *Coho salmon* Appendix II In: Gopalakrishnan KS, 1990: Studies on the effects of some pesticides on the fish *Etroplus maculatus* (Bloch), Ph. D Thesis, Cochin University of Science and Technology, Kerala,

India, 1979.
8. Kumar S, Tembhre M. Fish and Fisheries. New Central agencies (P) Ltd., London, 2010.
9. Machado M, Fanta E. Effects of the organophorous methyl parathion on the branchial epithelium of a freshwater fish *Metynnis roosevelti*. Braz Arch Boil Techn 2003; 46(3):361-372.
10. Mazon AF, Cerqueira CCC, Monteiro EAS, Fernandes MN. Acute copper exposure in freshwater fish Morphological and physiological effects. In: Val AL, Almeida-Val VMF, (Eds.), Biology of Tropical Fishes, INPA, Manaus, 1999; 263-275.
11. Morrison R, Nowak B Carson J. The histopathological effects of a levamisole-adjuvanted *Vibrio anguillarum* vaccine on Atlantic salmon (*Salmo salar* L.). Aquaculture 2001; 195:23-33.
12. Radhakrishnan Nair C. Studies on pesticide- induced changes in chosen fishes. Ph. D. Thesis, Manonmaniam Sundaranar University, Tirunelveli, India. 2002.
13. Richmonds C, Dutta HM. Histopathological changes induced by malathion in the gills of bluegill *Lepomis macrochirus*. Bull Environ Contam Toxicol 1989; 43:123-130.
14. Roy PK, Munshi JSD. Malathion induced structural and morphometric changes of gills of a freshwater major carp, *Cirrhinus mrigala* (Harr.) J Environ Biol 1991; 12(1):79-87.
15. Tilak KS, Koteswara RD, Veeraiah K. Effects of chloropyrifos on histopathology of fish *Catla catla*. J Ecotoxicol Environ Monitor 2005; 15(2):127-140.
16. Walsh AH, Ribelin WE. The pathology of pesticide poisoning In: Gopalakrishnan KS, 1990: Studies on the effects of some pesticides on the fish *Etroplus maculatus* (Bloch), Ph. D Thesis, Cochin University of Science and Technology, Kerala, India, 1975, 124-125.
17. Wijeyaratne W, Pathirxatne A. Acetylcholinesterase inhibition and gill lesions in *Rasbora caverii*, an indigenous fish inhabiting rice field associated water bodies in Sri Lanka. Ecotoxicology 2006; 15:609–619.